



HAL
open science

Hypersociability associated with developmental delay, macrocephaly and facial dysmorphism points to CHD3 mutations

Juliette Coursimault, François Lecoquierre, Pascale Saugier-Veber, Valérie Drouin-Garraud, Joël Lechevallier, Anne Boland, Jean-François Deleuze, Thierry Frebourg, Gaël Nicolas, Anne-Claire Brehin

► To cite this version:

Juliette Coursimault, François Lecoquierre, Pascale Saugier-Veber, Valérie Drouin-Garraud, Joël Lechevallier, et al.. Hypersociability associated with developmental delay, macrocephaly and facial dysmorphism points to CHD3 mutations. Eur J Med Genet, 2021, 64 (4), pp.104166. 10.1016/j.ejmg.2021.104166 . cea-04359967

HAL Id: cea-04359967

<https://cea.hal.science/cea-04359967>

Submitted on 22 Jul 2024

HAL is a multi-disciplinary open access archive for the deposit and dissemination of scientific research documents, whether they are published or not. The documents may come from teaching and research institutions in France or abroad, or from public or private research centers.

L'archive ouverte pluridisciplinaire **HAL**, est destinée au dépôt et à la diffusion de documents scientifiques de niveau recherche, publiés ou non, émanant des établissements d'enseignement et de recherche français ou étrangers, des laboratoires publics ou privés.



Distributed under a Creative Commons Attribution - NonCommercial 4.0 International License

Hypersociability associated with developmental delay, macrocephaly and facial dysmorphism points to CHD3 mutations

Juliette Coursimault¹, François Lecoquierre¹, Pascale Saugier-Veber¹, Valérie Drouin-Garraud², Joël Lechevallier³, Anne Boland⁴, Jean-François Deleuze⁴, Thierry Frebourg¹, Gaël Nicolas¹, Anne-Claire Brehin¹

¹Normandie Univ, UNIROUEN, Inserm U1245 and Rouen University Hospital, Department of Genetics and Reference Center for Developmental Disorders, Normandy Center for Genomic and Personalized Medicine, F-76000, Rouen, France

²Department of Pediatrics, Rouen University Hospital, F-76000, Rouen, France

³Department of Pediatric Surgery, Rouen University Hospital, F-76000, Rouen, France

⁴Centre National de Recherche en Génomique Humaine, Institut de Biologie François Jacob, CEA, Université Paris-Saclay, Evry, France

Corresponding author: Anne-Claire Bréhin, Unité de Génétique Clinique, CHU de Rouen, 37 Boulevard Gambetta, 76031 ROUEN Cedex, France. Telephone number :+33232888747. Fax number: +33232888746. E-mail: anne-claire.brehin@chu-rouen.fr

ABSTRACT

CHD3-related syndrome, also known as Snijders Blok-Campeau syndrome, is a rare developmental disorder described in 2018, caused by *de novo* pathogenic variants in the *CHD3* gene. This syndrome is characterized by global developmental delay, speech delay, intellectual disability, hypotonia and behavioral disorders including autism spectrum disorder (ASD). Typical dysmorphic features include macrocephaly, hypertelorism, enophthalmia, sparse eyebrows, bulging forehead, midface hypoplasia, prominent nose and pointed chin. To our knowledge, there have been no other clinical descriptions of patients since the initial publication. .

We report the clinical description of a 21-year-old patient harboring a pathogenic *de novo* variant in *CHD3*. We reviewed the clinical features of the 35 previously reported patients. Main features were severe intellectual disability, dysmorphic facies, macrocephaly, cryptorchidism, pectus carinatum, severe ophthalmologic abnormalities and behavioral disorders including ASD, and a frank happy demeanor. Hypersociability, which was a noticeable clinical feature in our case, despite ASD, is an uncommon behavioral feature in syndromic intellectual disabilities. Our report supports hypersociability as a suggestive feature of CHD3-related syndrome along with developmental delay, macrocephaly and a dysmorphic facies.

KEYWORDS

Snijders Blok-Campeau syndrome; SNIBCPS; *CHD3*; hypersociability; happy demeanor; macrocephaly

INTRODUCTION

A novel developmental disorder was described in 2018 following the identification of a *de novo* missense mutation in the *CHD3* gene in a child diagnosed with Childhood Apraxia of Speech (CAS)(Snijders Blok et al., 2018, Eising et al., 2019). A series of 35 patients with *de novo* CHD3 mutations was assembled using the exchange platform GeneMatcher (Sobreira et al., 2015), allowing the phenotypic description of the CHD3-related syndrome (OMIM # 618205, Snijders Blok-Campeau Syndrome; SNIBCPS) (Snijders Blok et al., 2018). Affected individuals all showed global developmental delay and/or intellectual disability and speech delay. Other features included macrocephaly, visual abnormalities, characteristic facial features such as prominent forehead and hypertelorism, hypotonia, and joint laxity.

We report here the clinical description of a 21-year-old patient presenting marked hypersociability in the context of severe intellectual disability, autism spectrum disorder, dysmorphic facies, congenital abnormalities and macrocephaly.

CLINICAL REPORT

The patient was initially evaluated at birth because of dysmorphic craniofacial features and hypotonia. Parents were not consanguineous and both presented a normal neurodevelopment. The mother was a 25-year-old primiparous woman; she presented a juvenile form of Parkinson's disease of unknown etiology, diagnosed at 39 years of age. The 26-year-old father had a no medical history. Pregnancy was marked by high biparietal diameter and bilateral pyelocaliceal dilatation diagnosed by prenatal ultrasonography later confirmed after birth. The amniotic fluid was unremarkable. The patient was born at 38 weeks of gestation by cesarean section for fetal distress. At birth, Apgar scores were 4/6 at 1/5 minutes, respectively, head circumference was 37.2 cm (+2.2 SD), length 51 cm (+0.7 SD), and weight 3040 g (-0.3 SD) (Chou JH et al., 2020). Transfontanellar ultrasound revealed bilateral temporo-fronto-parietal subdural effusions. At the age of 6 months, brain magnetic resonance imaging (MRI) showed the persistence of these effusions with some delayed myelination. Ophthalmological examination showed convergent strabismus associated with severe limitation of bilateral abduction. Visual evoked response and

electroretinography were normal. He had no hearing loss and auditory evoked potential test was normal. At the age of 10 months, a brain computed tomography scan (CT-scan) showed large subarachnoid spaces in frontal regions, without ventricular dilatation. Electroencephalography was normal. Upon examination at the age of 16 months, he attained neck stability and head control, but was unable to sit or roll over. He was a calm, hypotonic and smiling child. He received physiotherapy sessions. At 6 years of age, he could walk unassisted; he could say a few words and associate two words. He said his first short sentences shortly before the age of 8 years. Other clinical findings included genitourinary tract abnormalities with cryptorchidism, high intergluteal cleft, left renal hypoplasia, and bilateral vesicoureteral reflux. The child also had scoliosis due to an asymmetry of the lower limbs related to an excess of inclination of the femoral necks (*coxa vara*). Upon physical examination at 19 years of age, head circumference was 60 cm (+2 SD), height was 171 cm (-1 SD) and weight was 45 kg (-3 SD). He had dysmorphic facial features including asymmetric face, brachycephaly, posterior plagiocephaly, large forehead, temporal retraction, thin and sparse eyebrows especially in the lateral third, telecanthus, hypertelorism, enophthalmia, strabismus, midface hypoplasia, broad nose, pointed chin, and dysplastic low-set posteriorly-rotated ears. He also presented *pectus carinatum*, arachnodactyly and abnormal dental implantation with thick gums (Figure 1).

Our patient was evaluated in an ASD reference center and fulfilled the diagnostic criteria for ASD following the 5th edition of Diagnostic and Statistical Manual of Mental Disorders (DSM-5) criteria. Diagnostic features included stereotypies, intolerance to change, restricted interests and deficient social comprehension (disorder in social reciprocity with inappropriate questions, difficulties in understanding relationships). He was also diagnosed with severe intellectual disability, associated with a frank happy demeanor. He could say short and simple sentences. He could understand simple commands. He was described as a very pleasant, compliant and smiling child by all neurologists, physiotherapists, paediatricians and clinical geneticists involved in his medical care. However, these descriptions remained subjective and no objective assessment was performed in the absence of adapted scales. He had no sleeping disorder. He attended a school for special needs.

Initial workup including a metabolic screen, standard karyotyping and screening for Fragile-X syndrome was normal. Array comparative genomic hybridization (Agilent, 105K) revealed a 51 kb 21q22.11 heterozygous deletion encompassing the *CRYZL1* gene (Hg18 Assembly: base pair coordinates 33883616-33934688). Targeted Quantitative Multiplex PCR of Short Fluorescent fragments analysis showed that this deletion was inherited from the mother. Hence, it was classified as likely benign, according to the parental analysis and the literature. Gene panel NGS sequencing of 456 genes associated with intellectual disability revealed no candidate variant.

Trio-based exome sequencing was subsequently performed following capture using a Sureselect human all exons V6 kit and 150 bp paired-end sequencing, ~120x average coverage, using an Illumina HiSeq4000 at the national research center in human genomics (CNRGH, CEA, Evry, France). Bioinformatics analyses were performed as previously described using a pipeline based on BWA, Picard, and GATK (Grangeon et al., 2019) as well as copy number variant analysis using a CANOES-based workflow (Quenez et al., 2021).

Variant interpretation followed the ACMG-AMP guidelines (Richards et al., 2015) and focused on *de novo*, autosomal recessive and X-linked scenarios. This approach identified a single *de novo* candidate variant in the *CHD3* gene: chr17(GRCh37):g.7803326A>G, NM_001005273.2:c.2657A>G, p.(His886Arg) (ClinVar access number : SUB8478021). This variant is absent from the gnomAD database (Karczewski et al., 2020). It has been observed in another patient from the original study (Snijders Blok et al., 2018) and was considered as likely pathogenic in two ClinVar entries. The affected amino acid residue lies in the helicase domain of *CHD3*, where most of the pathogenic variants have been identified. Multiple bioinformatics tools predicted a deleterious effect, including SIFT, Polyphen-2, Mutation taster and CADD with a score of 26. Altogether, this variant was considered as pathogenic (class 5) with complete contribution to the patient's phenotype.

DISCUSSION

We report a male patient with clinical and molecular findings consistent with the Snijders Blok-Campeau syndrome (SNIBCPS) or CHD3-related syndrome. Interestingly, our patient showed

hypersociability. We suggest that, when associated with global developmental delay and macrocephaly, it should represent a suggestive clinical feature of CHD3-related syndrome.

Hypersociability can be easily identified by clinicians but remains difficult to assess objectively as there are no standardized tests available, especially for individuals with intellectual disability. We discussed the use of the PSA (Profil Socio-Affectif) scale, which accurately describes the emotional and behavioral tendencies of children aged of 2½ to 6 years (LaFrenière P.J et al., 1997). However, we could not use it because of the patient's age and intellectual impairment. Because all healthcare professionals who met the patient described him as a very pleasant, friendly, compliant and smiling child, we concluded that he presents hypersociability. Hypersociability or over-friendliness is an uncommon behavioral feature in syndromic intellectual disabilities. It constitutes a recognizable feature that can contribute to the diagnosis of only a few chromosomal abnormalities and monogenic conditions, including Williams-Beuren syndrome (microdeletion of the 7q11.23 region) (Doyle et al., 2004; Frigerio et al., 2006; Klein-Tasman et al., 2018), Angelman syndrome (maternal deletion, paternal uniparental disomy involving chromosome 15q11.2-q13 or maternal *UBE3A* variations) (Toth, 2019), Down syndrome, Koolen de Vries syndrome (microdeletion of 17q21.31 region or heterozygous mutation in the *KANSL1* gene on chromosome 17q21.31) (Egger et al., 2013), Borjeson-Forssman-Lehmann syndrome (X-linked mutations in *PHF6*) (Visootsak et al., 2004), or Cohen syndrome (bi-allelic mutations in the *VPS13B/COH1* gene) (Kivitie-Kallio and Norio, 2001). These diagnoses were excluded in our patient by chromosomal microarray analysis, exome sequencing, and because other clinical features were not indicative of either syndrome.

While behavioral disorders such as anxiety, social withdrawal, and depression have been well described and studied in humans, the mechanism of hypersociability remains poorly understood. Two major pathophysiological pathways have been proposed to explain hypersociability. The first one is the ability of the amygdala to discriminate between fear-inducing and friendly social clues and to produce an appropriate behavioral response. The second one is the dopaminergic reward/aversion system that initiates approach or avoidance behavior depending of the social situation. Both systems seem to regulate social behavior but precise functions of human sociability

remain complex and not fully understood and how genetic defects in the above-mentioned syndromes putatively impact these pathways remains to be determined (Haas et al., 2010 ; Toth et al. 2019).

We analyzed the clinical features of all 36 patients including ours (Figure 2). Intellectual disability was reported in all cases (100%) with a wide range of severity (total IQ ranging from below 35 to values in the lower normal ranges, 70–85) along with global developmental delay. All the patients presented with impaired speech and language skills (100%) associated with features that included speech apraxia, dysarthria, oral motor problems, and stuttering that affected expressive more than receptive language abilities. Most of them had hypotonia (76%) and 87% showed motor delay. MRI was performed in some patients showing widening of cerebrospinal fluid spaces for 33% of the previously reported patients (Snijders Blok et al., 2018) as in our patient. Other clinical features included macrocephaly (58%) and a dysmorphic facies with prominent forehead, hypertelorism, broad and bossing forehead, periorbital fullness narrow palpebral fissures, laterally sparse eyebrows, low-set and often simple ears with thick helices, and a pointed chin. Autistic features were found in 29% of patients. Friendly and good social behaviors were reported in 14/28 (50%) patients. Some patients also presented ophthalmological abnormalities (strabismus, 30 %), joint laxity (40%), and genital abnormalities in males (35%).

Overall, our patient shares most of the features, such as hypotonia, ophthalmological abnormalities, gross and fine motor delay, macrocephaly and jovial behavior. He had dental and gum abnormalities like 34% of patients from the initial series (Snijders Blok et al., 2018). Interestingly, a mouse model implicated *Chd3* in tooth root development (Date et al., 2012). Concerning ophthalmological disorders, another patient who shares the same missense variation as our patient, was described with Brown syndrome (limited elevation of the eyes) which is an uncommon symptom. Our patient presented severe limitation of the abduction of both eyes. Scoliosis, joint hyperlaxity, strabismus, MRI abnormalities with broad subarachnoid spaces in frontal regions and numerous organ malformations such as cryptorchidism, high intergluteal cleft or anteriorly placed anus, V shaped sacral crease have been described in others patients (Snijders Blok et al., 2018).

Our patient also showed arachnodactyly, asymmetry of the lower limbs and renal abnormalities. These features had not been reported previously.

CHD3 encodes a subunit of the NuRD (Nucleosome Remodeling Desacetylase) complex, involved in chromatin remodeling and regulation of transcription. This complex includes CHD3 or CHD4 depending on cell types and physiological conditions. While the CHD3 protein is very similar to the CHD4 protein, they form two distinct isoforms of the NuRD complex.

CHD4-related syndrome, also called Sifrim-Hitz-Weiss syndrome (SIHIWES) has been reported in 37 patients described with cardiac defects, cerebral, ophthalmologic and skeletal anomalies, deafness and hypogonadism (Weiss et al., 2016, 2020). Another component of the NuRD complex, GATAD2B, has been associated with a neurodevelopmental disorder. GATAD2B-associated neurodevelopmental disorder (GAND) (Willemsen et al., 2013, Shieh et al., 2020) has been reported in patients presenting with intellectual disability, global delay, language impairment, hypotonia and dysmorphic features. Up to now, 78 patients have been described (Shieh et al., 2020, Vera et al., 2020). Both CHD4 and GATAD2B-related syndromes share some clinical features with the CHD3-related syndrome, such as developmental delay, intellectual impairment, hypotonia, macrocephaly and dysmorphic features, to which may be added variable congenital abnormalities. Thus, it has recently been suggested that these syndromes could be grouped under the name NuRDopathies (Pierson et al., 2019).

Interestingly, the majority of patients with *GATAD2B* variations are described with good eye contact and social reciprocity (Pierson et al., 2019; Shieh et al., 2020). To our knowledge, friendly and sociable behaviors have not been described in patients with CHD4-related syndrome (Weiss et al., 2020; Shieh et al., 2020). This behavioral feature is not often described and further studies may be needed to clarify the patients' behavioral phenotypes in NuRDopathies.

In conclusion, we identified a pathogenic variant in *CHD3* in a male patient diagnosed with a syndromic neurodevelopmental disorder. We describe additional clinical features associated with CHD3-related syndrome including arachnodactyly, asymmetry of the lower limbs and renal abnormalities. Furthermore, hypersociability is an uncommon behavioral feature in syndromic intellectual disabilities. We suggest that hypersociability or happy demeanor, when associated with

developmental delay, macrocephaly, and dysmorphic traits, may constitute a suggestive feature of *CHD3* mutations.

ACKNOWLEDGEMENTS

We thank Virginie Nguyen Viet, Nathalie Drouot and Séverine Fehrenbach for technical help as well as Gabriella Vera for her help in editing the manuscript. This study was cosupported by European Union and Région Normandie in the context of Recherche Innovation Normandie (RIN 2018, to PSV and GN). Europe gets involved in Normandie with the European Regional Development Fund (ERDF). Collaboration CEA-DRF-Jacob-CNRGH - CHU de Rouen. This work was generated within the European Reference Network for Developmental abnormalities and Intellectual Disability.

FIGURES Titles and Legends

Figure 1: Clinical characterization of the case – Frontal and lateral views of the proband at the age of 20 years. Note the large forehead, temporal retraction, thin and sparse eyebrows especially in the external third, telecanthus, hypertelorism, enophthalmia, strabismus, midface hypoplasia, broad nose, pointed chin, dental implantation abnormalities, and dysplastic low-set posteriorly-rotated ears.

Figure 2: Phenotypic and developmental characteristics of patients with CHD3 disorder – Patients that are positives for the listed features are figured in blue: dark blue for patients from Snijders Blok et al. and light blue for our patient. Patients without symptoms are shown in gray.

REFERENCES

Chou, JH., Roumiantsev, S., Singh, R. PediTools Electronic Growth Chart Calculators: Applications in Clinical Care, Research, and Quality Improvement. *J. Med Internet Res* 2020 ;22(1):e16204 URL: <https://www.jmir.org/2020/1/e16204> doi: 10.2196/16204 PMID: 32012066

Date, Y., Yokoyama, Y., Kondo, H., Kuroda, S., Ohya, K., Ota, M.S., Iseki, S., Kasugai, S., 2012. Restricted expression of chromatin remodeling associated factor Chd3 during tooth root development. *J. Periodontal Res.* 47, 180–187. <https://doi.org/10.1111/j.1600-0765.2011.01419.x>

Doyle, T.F., Bellugi, U., Korenberg, J.R., Graham, J., 2004. “Everybody in the world is my friend” hypersociability in young children with Williams syndrome. *Am. J. Med. Genet. A.* 124A, 263–273. <https://doi.org/10.1002/ajmg.a.20416>

Egger, J.I.M., Wingbermühle, E., Verhoeven, W.M.A., Dijkman, M., Radke, S., de Bruijn, E.R.A., de Vries, B., Kessels, R.P.C., Koolen, D., 2013. Hypersociability in the behavioral phenotype of 17q21.31 microdeletion syndrome. *Am. J. Med. Genet. A.* 161A, 21–26. <https://doi.org/10.1002/ajmg.a.35652>

Eising, E., Carrion-Castillo, A., Vino, A., Strand, E.A., Jakielski, K.J., Scerri, T.S., Hildebrand, M.S., Webster, R., Ma, A., Mazoyer, B., Francks, C., Bahlo, M., Scheffer, I.E., Morgan, A.T., Shriberg, L.D., Fisher, S.E., 2019. A set of regulatory genes co-expressed in embryonic human brain is implicated in disrupted speech development. *Mol. Psychiatry* 24, 1065–1078. <https://doi.org/10.1038/s41380-018-0020-x>

Frigerio E, Burt DM, Gagliardi C, et al. Is everybody always my friend? Perception of approachability in Williams syndrome. *Neuropsychologia.* 2006;44(2):254–259.

Grangeon, L., Wallon, D., Charbonnier, C., Quenez, O., Richard, A.-C., Rousseau, S., Budowski, C., Lebouvier, T., Corbille, A.-G., Vidailhet, M., Méneret, A., Roze, E., Anheim, M., Tranchant, C.,

Favrole, P., Antoine, J.-C., Defebvre, L., Ayrygnac, X., Labauge, P., Pariente, J., Clanet, M., Maltête, D., Rovelet-Lecrux, A., Boland, A., Deleuze, J.-F., French PFBC study group, Frebourg, T., Hannequin, D., Campion, D., Nicolas, G., 2019. Biallelic MYORG mutation carriers exhibit primary brain calcification with a distinct phenotype. *Brain J. Neurol.* 142, 1573–1586. <https://doi.org/10.1093/brain/awz095>

Haas, B.W., Hoefft, F., Searcy, Y.M., Mills, D., Bellugi, U., Reiss, A., 2010. Individual differences in social behavior predict amygdala response to fearful facial expressions in Williams syndrome. *Neuropsychologia* 48, 1283–1288. <https://doi.org/10.1016/j.neuropsychologia.2009.12.030>

Karczewski, K.J., Francioli, L.C., Tiao, G., Cummings, B.B., Alföldi, J., Wang, Q., Collins, R.L., Laricchia, K.M., Ganna, A., Birnbaum, D.P., Gauthier, L.D., Brand, H., Solomonson, M., Watts, N.A., Rhodes, D., Singer-Berk, M., England, E.M., Seaby, E.G., Kosmicki, J.A., Walters, R.K., Tashman, K., Farjoun, Y., Banks, E., Poterba, T., Wang, A., Seed, C., Whiffin, N., Chong, J.X., Samocha, K.E., Pierce-Hoffman, E., Zappala, Z., O'Donnell-Luria, A.H., Minikel, E.V., Weisburd, B., Lek, M., Ware, J.S., Vittal, C., Armean, I.M., Bergelson, L., Cibulskis, K., Connolly, K.M., Covarrubias, M., Donnelly, S., Ferreira, S., Gabriel, S., Gentry, J., Gupta, N., Jeandet, T., Kaplan, D., Llanwarne, C., Munshi, R., Novod, S., Petrillo, N., Roazen, D., Ruano-Rubio, V., Saltzman, A., Schleicher, M., Soto, J., Tibbetts, K., Tolonen, C., Wade, G., Talkowski, M.E., Neale, B.M., Daly, M.J., MacArthur, D.G., 2020. The mutational constraint spectrum quantified from variation in 141,456 humans. *Nature* 581, 434–443. <https://doi.org/10.1038/s41586-020-2308-7>

Kivitie-Kallio, S., Norio, R., 2001. Cohen syndrome: essential features, natural history, and heterogeneity. *Am. J. Med. Genet.* 102, 125–135. [https://doi.org/10.1002/1096-8628\(20010801\)102:2<125::aid-ajmg1439>3.0.co;2-0](https://doi.org/10.1002/1096-8628(20010801)102:2<125::aid-ajmg1439>3.0.co;2-0)

Klein-Tasman B., Van der Fluit F., Mervis C.. Autism Spectrum Symptomatology in Children with Williams Syndrome who have Phrase Speech or Fluent Language. *J Autism Dev Disord.* 2018 Sep; 48(9): 3037–3050.

LaFrenière P.J., Dumas J.E., Capuano F., Durning P. Profil socio-affectif (PSA): évaluation des compétences sociales et des difficultés d'adaptation des enfants de 2 ans 1/2 à 6 ans. ECPA, 1997

Pierson, T.M., Otero, M.G., Grand, K., Choi, A., Graham, J.M., Young, J.I., Mackay, J.P., 2019. The NuRD complex and macrocephaly associated neurodevelopmental disorders. *Am. J. Med. Genet. C Semin. Med. Genet.* 181, 548–556. <https://doi.org/10.1002/ajmg.c.31752>

Quenez O, Cassinari K, Coutant S, Lecoquierre F, Le Guennec K, Rousseau S, Richard AC, Vasseur S, Bouvignies E, Bou J, Lienard G, Manase S, Fourneaux S, Drouot N, Nguyen-Viet V, Vezain M, Chambon P, Joly-Helas G, Le Meur N, Castelain M, Boland A, Deleuze JF; FREX Consortium, Tournier I, Charbonnier F, Kasper E, Bougeard G, Frebourg T, Saugier-veber P, Baert-Desurmont S, Champion D, Rovelet-Lecrux A, Nicolas G. 2021. Detection of copy-number variations from NGS data using read depth information: a diagnostic performance evaluation. *Eur J Hum Genet.* 29(1):99-109. <https://doi: 10.1038/s41431-020-0672-2>.

Richards, S., Aziz, N., Bale, S., Bick, D., Das, S., Gastier-Foster, J., Grody, W.W., Hegde, M., Lyon, E., Spector, E., Voelkerding, K., Rehm, H.L., ACMG Laboratory Quality Assurance Committee, 2015. Standards and guidelines for the interpretation of sequence variants: a joint consensus recommendation of the American College of Medical Genetics and Genomics and the Association for Molecular Pathology. *Genet. Med. Off. J. Am. Coll. Med. Genet.* 17, 405–424. <https://doi.org/10.1038/gim.2015.30>

Shieh, C., Jones, N., Vanle, B., Au, M., Huang, A.Y., Silva, A.P.G., Lee, H., Douine, E.D., Otero, M.G., Choi, A., Grand, K., Taff, I.P., Delgado, M.R., Hajianpour, M.J., Seeley, A., Rohena, L., Vernon, H., Gripp, K.W., Vergano, S.A., Mahida, S., Naidu, S., Sousa, A.B., Wain, K.E., Challman, T.D., Beek, G., Basel, D., Ranells, J., Smith, R., Yusupov, R., Freckmann, M.-L., Ohden, L., Davis-Keppen, L., Chitayat, D., Dowling, J.J., Finkel, R., Dauber, A., Spillmann, R., Pena, L.D.M., Undiagnosed Diseases Network, Metcalfe, K., Splitt, M., Lachlan, K., McKee, S.A., Hurst, J., Fitzpatrick, D.R., Morton, J.E.V., Cox, H., Venkateswaran, S., Young, J.I., Marsh, E.D., Nelson, S.F., Martinez, J.A., Graham, J.M., Kini, U., Mackay, J.P., Pierson, T.M., 2020. GATAD2B-associated neurodevelopmental disorder (GAND): clinical and molecular insights into a NuRD-related disorder. *Genet. Med. Off. J. Am. Coll. Med. Genet.* <https://doi.org/10.1038/s41436-019-0747-z>

Snijders Blok, L., Rousseau, J., Twist, J., Ehresmann, S., Takaku, M., Venselaar, H., Rodan, L.H., Nowak, C.B., Douglas, J., Swoboda, K.J., Steeves, M.A., Sahai, I., Stumpel, C.T.R.M., Stegmann, A.P.A., Wheeler, P., Willing, M., Fiala, E., Kochhar, A., Gibson, W.T., Cohen, A.S.A., Agbahovbe, R., Innes, A.M., Au, P.Y.B., Rankin, J., Anderson, I.J., Skinner, S.A., Louie, R.J., Warren, H.E., Afenjar, A., Keren, B., Nava, C., Buratti, J., Isapof, A., Rodriguez, D., Lewandowski, R., Propst, J., van Essen, T., Choi, M., Lee, S., Chae, J.H., Price, S., Schnur, R.E., Douglas, G., Wentzensen, I.M., Zweier, C., Reis, A., Bialer, M.G., Moore, C., Koopmans, M., Brilstra, E.H., Monroe, G.R., van Gassen, K.L.I., van Binsbergen, E., Newbury-Ecob, R., Bownass, L., Bader, I., Mayr, J.A., Wortmann, S.B., Jakielski, K.J., Strand, E.A., Kloth, K., Bierhals, T., DDD study, Roberts, J.D., Petrovich, R.M., Machida, S., Kurumizaka, H., Lelieveld, S., Pfundt, R., Jansen, S., Deriziotis, P., Faivre, L., Thevenon, J., Assoum, M., Shriberg, L., Kleefstra, T., Brunner, H.G., Wade, P.A., Fisher, S.E., Campeau, P.M., 2018a. CHD3 helicase domain mutations cause a neurodevelopmental syndrome with macrocephaly and impaired speech and language. *Nat. Commun.* 9, 4619. <https://doi.org/10.1038/s41467-018-06014-6>

Sobreira, N., Schiettecatte, F., Valle, D., Hamosh, A., 2015. GeneMatcher: a matching tool for connecting investigators with an interest in the same gene. *Hum. Mutat.* 36, 928–930. <https://doi.org/10.1002/humu.22844>

Toth, M., 2019. The other side of the coin: Hypersociability. *Genes Brain Behav.* 18, e12512. <https://doi.org/10.1111/gbb.12512>

Vera G, Sorlin A, Delplancq G, Lecoquierre F, Brasseur-Daudruy M, Petit F, Smol T, Ziegler A, Bonneau D, Colin E, Mercier S, Cogné B, Bézieau S, Edery P, Lesca G, Chatron N, Sabatier I, Duban-Bedu B, Colson C, Piton A, Durand B, Capri Y, Perrin L, Wiesener A, Zweier C, Maroofian R, Carroll CJ, Galehdari H, Mazaheri N, Callewaert B, Giuliano F, Zaafrane-Khachnaoui K, Buchert-Lo R, Haack T, Magg J, Rieß A, Blandfort M, Waldmüller S, Horber V, Leonardi E, Polli R, Turolla L, Murgia A, Frebourg T, Lebre AS, Nicolas G, Saugier-veber P, Guerrot AM. Clinical and molecular description of 19 patients with GATAD2B-Associated Neurodevelopmental Disorder (GAND). *Eur J Med Genet.* 2020 Oct;63(10):104004. doi: 10.1016/j.ejmg.2020.104004. Epub 2020 Jul 17. PMID: 32688057.

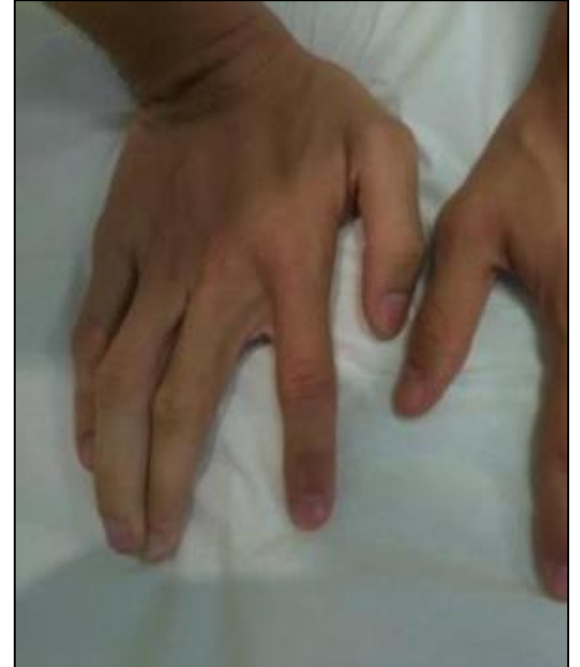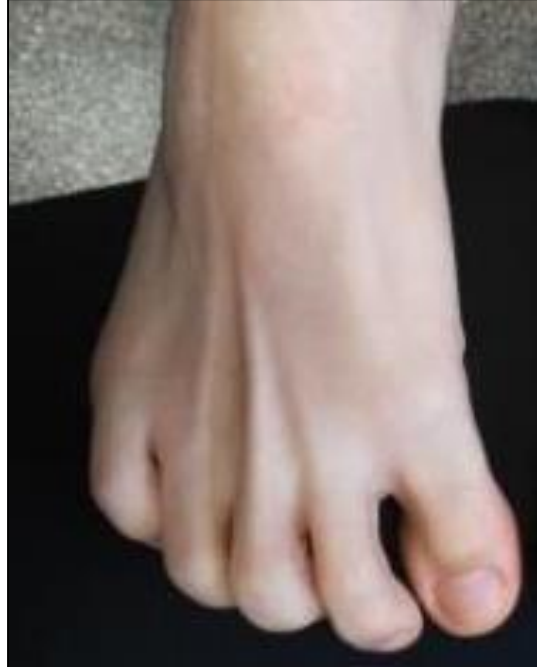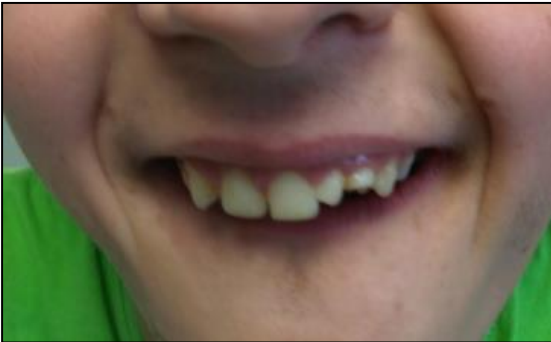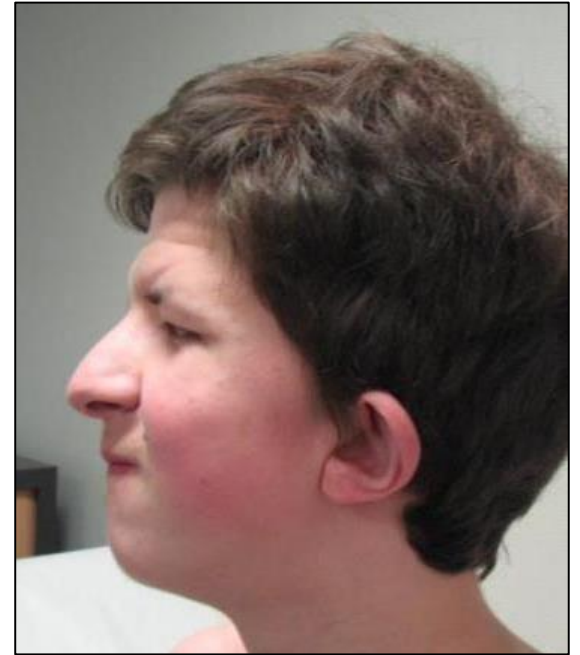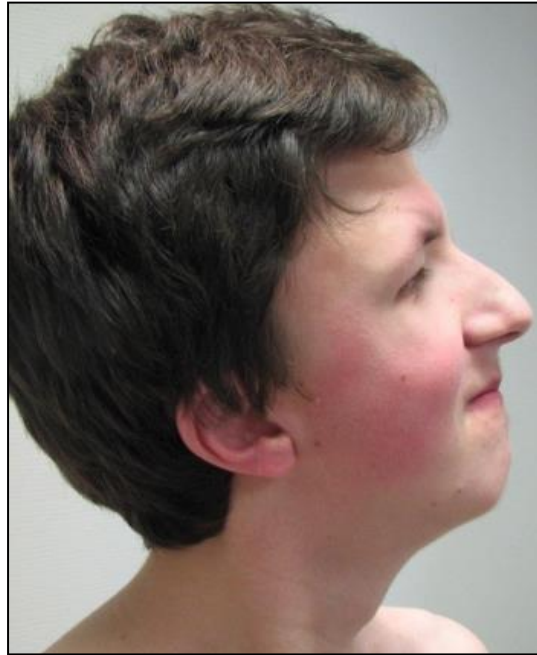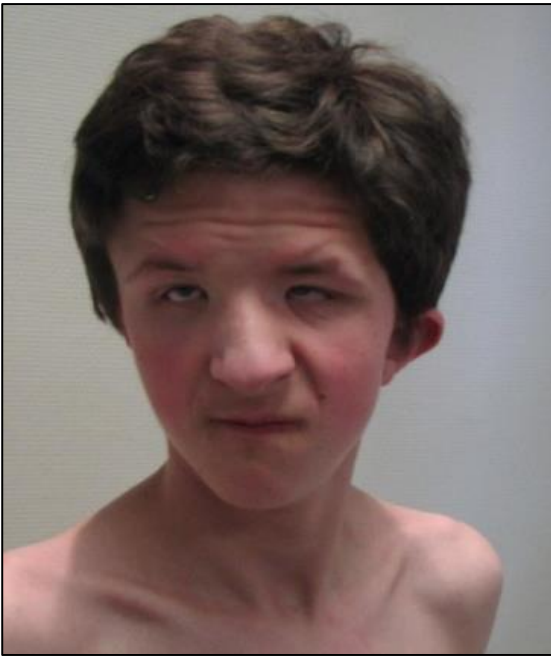Visootsak, J., Rosner, B., Dykens, E., Schwartz, C., Hahn, K., White, S.M., Szeftel, R., Graham, J.M., 2004. Clinical and behavioral features of patients with Borjeson-Forssman-Lehmann syndrome with mutations in PHF6. *J. Pediatr.* 145, 819–825. <https://doi.org/10.1016/j.jpeds.2004.07.041>

Weiss, K., Lazar, H.P., Kurolap, A., Martinez, A.F., Paperna, T., Cohen, L., Smeland, M.F., Whalen, S., Heide, S., Keren, B., Terhal, P., Irving, M., Takaku, M., Roberts, J.D., Petrovich, R.M., Schrier Vergano, S.A., Kenney, A., Hove, H., DeChene, E., Quinonez, S.C., Colin, E., Ziegler, A., Rumpel, M., Jain, M., Monteil, D., Roeder, E.R., Nugent, K., van Haeringen, A., Gambello, M., Santani, A., Medne, L., Krock, B., Skraban, C.M., Zackai, E.H., Dubbs, H.A., Smol, T., Ghoumid, J., Parker, M.J., Wright, M., Turnpenny, P., Clayton-Smith, J., Metcalfe, K., Kurumizaka, H., Gelb, B.D., Baris Feldman, H., Campeau, P.M., Muenke, M., Wade, P.A., Lachlan, K., 2020a. The CHD4-related

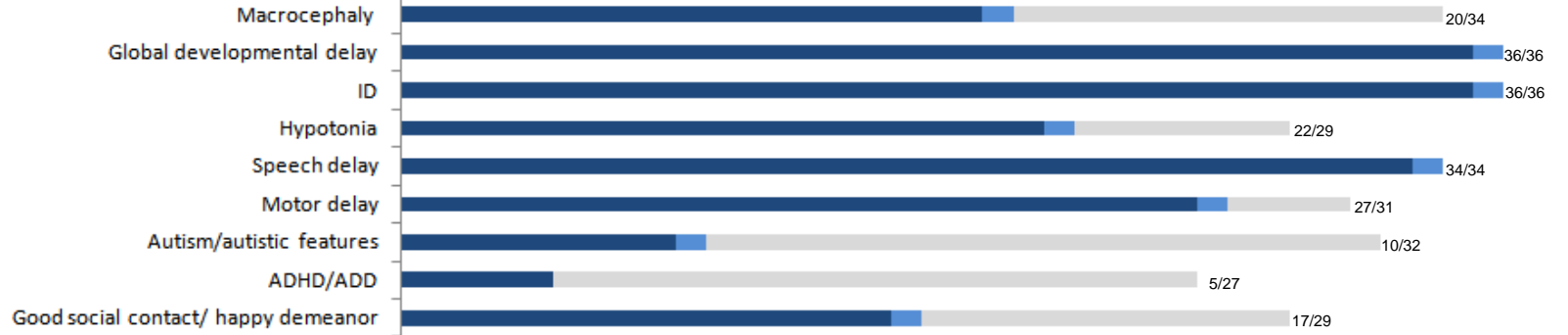
syndrome: a comprehensive investigation of the clinical spectrum, genotype-phenotype correlations, and molecular basis. *Genet. Med. Off. J. Am. Coll. Med. Genet.* 22, 389–397.
<https://doi.org/10.1038/s41436-019-0612-0>

Weiss, K., Terhal, P.A., Cohen, L., Bruccoleri, M., Irving, M., Martinez, A.F., Rosenfeld, J.A., Machol, K., Yang, Y., Liu, P., Walkiewicz, M., Beuten, J., Gomez-Ospina, N., Haude, K., Fong, C.-T., Enns, G.M., Bernstein, J.A., Fan, J., Gotway, G., Ghorbani, M., DDD Study, van Gassen, K., Monroe, G.R., van Haften, G., Basel-Vanagaite, L., Yang, X.-J., Campeau, P.M., Muenke, M., 2016. De Novo Mutations in CHD4, an ATP-Dependent Chromatin Remodeler Gene, Cause an Intellectual Disability Syndrome with Distinctive Dysmorphisms. *Am. J. Hum. Genet.* 99, 934–941.
<https://doi.org/10.1016/j.ajhg.2016.08.001>

Willemsen, M.H., Nijhof, B., Fenckova, M., Nillesen, W.M., Bongers, E.M.H.F., Castells-Nobau, A., Asztalos, L., Viragh, E., van Bon, B.W.M., Tezel, E., Veltman, J.A., Brunner, H.G., de Vries, B.B.A., de Ligt, J., Yntema, H.G., van Bokhoven, H., Isidor, B., Le Caignec, C., Lorino, E., Asztalos, Z., Koolen, D.A., Vissers, L.E.L.M., Schenck, A., Kleefstra, T., 2013. GATAD2B loss-of-function mutations cause a recognisable syndrome with intellectual disability and are associated with learning deficits and synaptic undergrowth in *Drosophila*. *J. Med. Genet.* 50, 507–514.
<https://doi.org/10.1136/jmedgenet-2012-101490>



Development



Malformations

