



HAL
open science

Vascularization of the lateral and medial antebrachial cutaneous nerves by cutaneous perforator arteries: An anatomical study

M. Cegarra-Escolano, C. Jaloux, M.-A. Poumellec, T. Balaguer, P. Baqué, N. Bronsard, O. Camuzard

► To cite this version:

M. Cegarra-Escolano, C. Jaloux, M.-A. Poumellec, T. Balaguer, P. Baqué, et al.. Vascularization of the lateral and medial antebrachial cutaneous nerves by cutaneous perforator arteries: An anatomical study. *Hand Surgery and Rehabilitation*, 2021, 40 (3), pp.241-249. 10.1016/j.hansur.2021.01.007 . cea-03615031

HAL Id: cea-03615031

<https://cea.hal.science/cea-03615031>

Submitted on 24 May 2023

HAL is a multi-disciplinary open access archive for the deposit and dissemination of scientific research documents, whether they are published or not. The documents may come from teaching and research institutions in France or abroad, or from public or private research centers.

L'archive ouverte pluridisciplinaire **HAL**, est destinée au dépôt et à la diffusion de documents scientifiques de niveau recherche, publiés ou non, émanant des établissements d'enseignement et de recherche français ou étrangers, des laboratoires publics ou privés.



Distributed under a Creative Commons Attribution - NonCommercial 4.0 International License

Vascularization of the lateral and medial antebrachial cutaneous nerves by cutaneous perforator arteries: An anatomical study

Vascularisation des nerfs cutanés latéral et médial de l'avant-bras par les artères perforantes cutanées : Étude anatomique

M. Cegarra-Escolano¹, C. Jaloux², M.-A. Poumellec¹, T. Balaguer¹, P. Baqué^{3,4}, N. Bronsard^{3,5}, O. Camuzard^{1,3,6}

1: Department of Plastic and Reconstructive Surgery, Institut Universitaire Locomoteur & Sport (iULS), University of Côte d'Azur, Hôpital Pasteur 2, 30 Voie romaine, 06000 Nice, France

2: Department of Plastic and Reconstructive Surgery, La Conception Hospital, Marseille, France

3: Laboratoire d'Anatomie Normale, Faculté de Médecine de Nice, University of Côte d'Azur, 28 Avenue de Valombrose, 06107 Nice, France.

4: Service de Chirurgie viscérale d'urgence, Hôpital Pasteur 2, University of Côte d'Azur, 30 Voie romaine, 06000 Nice, France

5: Department of Orthopedic Surgery, Institut Universitaire Locomoteur & Sport (iULS), University of Côte d'Azur, Hôpital Pasteur 2, 30 Voie romaine, 06000 Nice, France.

6: UMR E-4320 TIRO-MATOs CEA/DRF/BIAM, University of Côte d'Azur, 28 Avenue de Valombrose, 06107 Nice, France.

Corresponding author:

Oliver Camuzard

Institut Universitaire Locomoteur et du Sport (IULS), Service de Chirurgie Réparatrice et de la Main, CHU de Nice, Hôpital Pasteur 2, Nice, France

Laboratoire d'Anatomie humaine, Faculté de Médecine de Nice, Université Côte d'Azur
(UCA) France, Avenue de Valombrose, 06107 Nice cedex 2, France.

Phone: +33 4 93 37 77 06

Fax: +33 4 93 53 30 71

Email: camuzard.olivier@hotmail.fr

Other authors:

Marianne **CEGARRA-ESCOLANO**, M.D.

Charlotte **JALOUX**, M.D.

Marie-Anne **POUMELLEC**, M.D.

Thierry **BALAGUER**, M.D. Ph.D.

Patrick **BAQUÉ**, M.D. Ph.D.

Nicolas **BRONSARD**, M.D., Ph.D.

Keywords: Nerve vascularization; Vascularized nerve graft; Forearm cutaneous nerves;
Palmar digital nerve repair; Anatomical study; Perforator artery

Declaration of conflict of interest:

The authors declare no conflict of interest.

Funding:

The authors declared no potential conflicts of interest with respect to the research, authorship, and/or publication of this article.

Short title: Lateral and medial antebrachial cutaneous nerves vascularization: An anatomical study

Listing of each author's role/participation in the authorship of the manuscript

Marianne **CEGARRA-ESCOLANO**, M.D.:

- principal investigator with substantial contributions to conception and design,
- revision of the article,
- final approval of the version to be published,
- agreement to be accountable for all aspects of the work in ensuring that questions related to the accuracy or integrity of any part of the work are appropriately investigated and resolved

Charlotte **JALOUX**, M.D.:

- substantial contributions to conception and design,
- revision of the article,
- final approval of the version to be published,
- agreement to be accountable for all aspects of the work in ensuring that questions related to the accuracy or integrity of any part of the work are appropriately investigated and resolved

Marie-Anne **POUMELLEC**, M.D.:

- analysis and interpretation of data,
- revision of the article,
- final approval of the version to be published,
- agreement to be accountable for all aspects of the work in ensuring that questions related to the accuracy or integrity of any part of the work are appropriately investigated and resolved

Thierry **BALAGUER**, M.D. Ph.D.:

- analysis and interpretation of data,
- revision of the article,

- final approval of the version to be published,
- agreement to be accountable for all aspects of the work in ensuring that questions related to the accuracy or integrity of any part of the work are appropriately investigated and resolved

Patrick **BAQUÉ**, M.D. Ph.D.:

- analysis and interpretation of data,
- revision of the article,
- final approval of the version to be published,
- agreement to be accountable for all aspects of the work in ensuring that questions related to the accuracy or integrity of any part of the work are appropriately investigated and resolved

Nicolas **BRONSARD**, M.D. Ph.D.:

- analysis and interpretation of data,
- revision of the article,
- final approval of the version to be published,
- agreement to be accountable for all aspects of the work in ensuring that questions related to the accuracy or integrity of any part of the work are appropriately investigated and resolved

Olivier **CAMUZARD**, M.D Ph.D.:

- principal investigator with substantial contributions to conception and design,
- revision of the article,
- final approval of the version to be published,
- agreement to be accountable for all aspects of the work in ensuring that questions related to the accuracy or integrity of any part of the work are appropriately investigated and resolved

1 **Abstract**

2 The forearm is an interesting donor site for non-vascularized nerve grafts, especially hand
3 surgeons. Very few studies have described the use of the lateral and medial antebrachial
4 cutaneous nerves (LABCN and MABCN, respectively) as vascularized nerve grafts (VNGs).
5 The aim of this anatomical study was to analyze the characteristics and vascularization of
6 these nerves to describe new potential donor sites for VNGs. Twelve forearms were
7 dissected from fresh cadavers injected with red latex. The number of terminal branches,
8 lengths, and proximal and distal diameters of both the LABCN and MABCN were studied. An
9 anatomical description of the cutaneous perforator arteries from the radial and ulnar arteries
10 that vascularized the nerve was also recorded: number of perforators, length, type of
11 perforator (septo- or musculocutaneous), and location within the forearm (proximal, middle,
12 and distal third). In over 80% of the specimens, the cutaneous perforator arteries from the
13 radial and ulnar artery vascularized the LABCN and the MABCN, respectively. These
14 arteries, found mostly in the proximal third of the forearm, had diameters >0.5 mm. Most of
15 them came from the radial and ulnar arteries (for LABCN and MABCN vascularization,
16 respectively). In over 75% of the specimens, the nutrient arteries of both nerves also
17 vascularized the superficial veins and the skin. We found that these nerves are vascularized
18 by perforators arteries, which also participate in vein and skin vascularization. Altogether,
19 this anatomical study shows that reconstructive surgeons could use new VNGs based on the
20 perforator artery of the forearm.

21

22 **Résumé**

23 L'avant-bras est un site donneur intéressant de greffe nerveuse non vascularisée. Très peu
24 d'études se sont intéressées à l'utilisation des nerfs cutanés latéral et médial de l'avant-bras
25 (NCLAB et NCMAB) comme potentielle greffe nerveuse vascularisée (GNV). L'objectif de
26 cette étude anatomique était d'analyser les caractéristiques et la vascularisation de ces

27 nerfs afin de décrire de nouveaux sites de GNV. Douze avant-bras ont été disséqués à partir
28 de cadavres fraîchement injectés de latex rouge. Le nombre de branches terminales, la
29 longueur et les diamètres proximaux et distaux des NCLAB et NCMAB ont été étudiés. Les
30 caractéristiques anatomiques des artères perforantes cutanées des artères radiale et ulnaire
31 qui vascularisent ces nerfs sont également rapportées : nombre d'artère perforantes,
32 longueur, type (septo- ou musculo-cutané) et localisation dans la région de l'avant-bras (tiers
33 proximal, moyen et distal). Dans plus de 80 % des cas, les artères perforantes cutanées de
34 l'artère radiale ou ulnaire participaient à la vascularisation des NCLAB et NCMAB
35 respectivement. Ces artères, situées pour la plupart dans le tiers proximal de l'avant-bras,
36 avaient un diamètre > 0,5 mm et provenaient des artères radiale (NCLAB) et ulnaire
37 (NCMAB). Dans plus de 75 % des cas, ces artères vascularisaient également les veines
38 superficielles et la peau. Nous avons observé que ces nerfs sensitifs superficiels de l'avant-
39 bras étaient vascularisés par des artères perforantes cutanées. Ces artères participent
40 également à la vascularisation des veines superficielles. Au total, cette étude anatomique
41 indique que les chirurgiens reconstructeurs pourraient utiliser de nouveaux nerfs
42 vascularisés basés sur les artères perforantes de l'avant-bras.

43

44 *Keywords:* Nerve vascularization; Vascularized nerve graft; Forearm cutaneous nerves;
45 Lateral antebrachial cutaneous nerve; Medial antebrachial cutaneous nerve; Palmar digital
46 nerve repair; Anatomical study; Perforator artery; Perforator flap

47

48 *Mots-clés :* Vascularisation nerveuse; Greffe nerveuse vascularisée; Nerfs cutanés de
49 l'avant-bras; Nerf cutané latéral de l'avant-bras; Nerf cutané médial de l'avant-bras;
50 Réparation des nerfs digitaux palmaires; Étude anatomique; Artère perforante; Lambeau
51 perforant

52

53 **1. Introduction**

54 The forearm is an interesting donor site for nerve reconstruction, especially for hand
55 surgeons. Non-vascularized superficial cutaneous nerve grafts are usually used as donor
56 sites in the forearm. They can be easily raised into the subcutaneous tissue of the forearm
57 with low donor site morbidity [1–5]. This makes them the ideal nerves for upper arm—
58 especially digital nerve—reconstructions [3–6]. These nerves are usually used as non-
59 vascularized nerves but can be used as vascularized nerve grafts (VNGs). For this, the
60 exact anatomy of the vasculature supplying the superficial cutaneous nerves should be well
61 known.

62 Few studies have focused on this vascular anatomy of the superficial cutaneous nerves of
63 the body. Taylor et al. examined the source arterial supply of each peripheral nerve in the
64 extremities and assessed the potential of each nerve’s segment for VNGs [7,8]. Most of the
65 studies assessed deep subfascial nerves (e.g.: median or sciatic nerves) and did not focus
66 on superficial cutaneous nerves (e.g.: sural or saphenous nerves). In 1998, Nakajima et al.
67 described the anatomy of the source artery for the superficial cutaneous nerves and veins in
68 the extremities [9]. Similar to Taylor et al., Nakajima et al. found that arteries that
69 vascularized cutaneous nerves of the upper and lower extremities were cutaneous perforator
70 arteries [7,9]. Then, Masquelet et al. showed in an anatomical and clinical study of the leg
71 that the vascularization of the superficial nerves (sural, saphenous, and superficial fibular
72 nerves) comes from septocutaneous arteries arising from a deep source vessel [10]. In
73 addition, these arteries gave off several cutaneous branches in the suprafascial course of
74 the nerve. These results provided the basis for the design of skin flaps along neurovascular
75 systems—the neuroskin flap [10]. Bertelli et al. studied the vascularization of the sensory
76 nerves of the forearm in order to describe neurocutaneous axial island flaps to cover defects
77 in the distal part of the forearm and the hand [11–13]. Vascularization of nerves of the upper
78 and lower extremities came from cutaneous perforator arteries [9,14].

79 To the best of our knowledge, very few studies have described the use of the lateral
80 and medial antebrachial cutaneous nerves (LABCN and MABCN, respectively) as VNGs

81 [15,16]. Like the superficial cutaneous nerve of the leg (e.g.: sural and saphenous nerves),
82 we believe that these two forearm nerves (LABCN and MABCN) could be potential new
83 donor sites for VNGs. In this anatomical study, we wanted to investigate the vascular
84 anatomy of the LABCN and MABCN, describing the origin, localization, and anatomical
85 characteristics of the forearm's perforator arteries and veins that vascularize these two
86 nerves to discuss the possibility of using them as free VNGs.

87

88 **2. Materials and methods**

89 2.1. Preparation of specimens and dissections

90 In this cadaver study, we used 12 forearms from fresh cadavers (within 5 days of death). All
91 dissections were performed after red latex was injected into the vascular network, as
92 described by Peng et al. [17]. No funding was needed since our facility's anatomy laboratory
93 provided the specimens and the other materials used in the study free of cost. The brachial
94 arteries were injected with 60 cm³ of a red-colored latex solution (Esprit Composite, Paris,
95 France) at the middle third of the arm. Next, the arms were placed in a refrigerator at 4°C for
96 48 hours. Dissections were performed by the same surgeon using 3.5x magnification loupes
97 and a Vernier caliper (0.05 mm precision) made by Wiha Tools ® (Schonach, Germany).

98

99 2.2. Anatomical description of the forearm cutaneous nerves (LABCN and MABCN)

100 An incision was made on the palmar side of the forearm, from the elbow to the wrist crease.
101 The dissection started with skin removal and proceeded with the raising of the suprafascial
102 layer and the identification of the superficial veins, nerves, and arterial perforators. LABCN
103 and MABCN were dissected from where they pierced the deep fascia to become superficial
104 to the wrist crease. The following characteristics were recorded for LABCN and MABCN:
105 number of terminal branches, length of the fascial piercing point to the wrist crease, and the
106 proximal diameters of the main branch (anterior division of both nerves).

107

108 2.3. Anatomical description of nerve vascularization

109 We dissected the cutaneous perforator arteries with a proximal diameter >0.5 mm (named
110 “clinically significant” perforators) originating from the radial and ulnar arteries. The following
111 characteristics were recorded for perforators with a diameter > 0.5 mm: number of
112 perforators, length of the perforator artery from its source artery (radial or ulnar artery) to its
113 entry into the subcutaneous adipose tissue, type of perforator (septo- or musculocutaneous),
114 and location within the forearm (proximal, middle, and distal third).

115 We named the nerve nutrient arteries “nerve perforating arteries” or “nerve perforators”
116 as an analogy to the cutaneous perforating arteries. All nerve perforators were dissected
117 from the cutaneous nerves to their origins in the source arteries of the upper limb (radial,
118 ulnar, anterior, and posterior interosseous arteries). We highlighted the perforators with
119 diameters >0.5 mm. We recorded their types according to the classifications described by
120 Taylor et al. and Nakajima et al. [9,18]. We measured the perforators’ lengths and recorded
121 the positions of their meeting points with the nerves along a proximal to distal axis between
122 the elbow and wrist creases and divided them into proximal, middle, and distal thirds (Fig. 1).
123 We also described the vascular intrinsic and extrinsic neurovascular systems of the nerves.
124 The presence of neurocutaneous arteries or common vascularization with a vein was
125 recorded.

126

127 *2.4. Statistical analysis*

128 The data are presented as mean \pm standard deviation (SD) and were processed using
129 Microsoft Excel 2008 (Microsoft Corp, Redmond, Washington).

130

131 **3. Results**

132 3.1. Lateral antebrachial cutaneous nerve (LABCN)

133 *3.1.1. Anatomical characteristics*

134 The LABCN is the terminal sensory branch of the musculocutaneous nerve. After supplying
135 the coracobrachialis, biceps brachialis, and brachialis muscles, the musculocutaneous nerve

136 continues its course between the brachialis and biceps brachialis. It then goes under the
137 lateral margin of the biceps tendon until it finally pierces the deep fascia to become a
138 superficial and sensory nerve (innervating the lateral aspect of the anterior and posterior
139 forearm).

140 First, we found that the LABCN divided into two or three terminal branches ($2.17 \pm$
141 0.58 mm) along its course in the forearm (named anterior or posterior division). We found
142 this division of the LABCN at the level where the nerve reached the cephalic vein: junction of
143 the proximal and middle thirds of the forearm (Table 1). The anterior branch was constant
144 and had a larger diameter. It joined the region at the elbow crease under the basilic and
145 cephalic antebrachial veins. The anterior branch measured more than 1.5 mm in diameter
146 (1.66 ± 0.55 mm) and had a mean length of 200 ± 20 mm. The posterior branch was present
147 in 92% of the specimens. It was lateral to the cephalic vein and to the muscle belly of the
148 brachioradialis. Its mean diameter was 1.2 ± 0.48 mm, and its mean length was 140 ± 35
149 mm. When a third branch was present (25% of the specimens), it was located posteriorly
150 and progressed down the posterior border of the muscle bellies of the brachioradialis and
151 extensor carpi radialis longus muscles (Tables 1 and 2).

152

153 *3.1.2. LABCN nerve vascularization*

154 The LABCN received several nutrient vessels. All of these were provided by radial
155 artery perforators in every dissection. We found that all LABCNs had both intrinsic and
156 extrinsic neurovascular systems spanning their entire length, including the anterior and
157 posterior divisions. In total, several segmental vessels (perforator arteries) participated in
158 LABCN vascularization. There were 7-8 segmental perforator arteries in the forearm (all
159 cutaneous perforators).

160 Regarding the anterior branch of the LABCN (Fig. 2), we found 3.7 ± 1.1 perforator
161 arteries with diameters greater than 0.5 mm: 52% were in the proximal third, 35% in the

162 middle third, and 13% in the distal third (Tables 2 and 3). They were mostly (85%) direct
163 cutaneous perforators (septocutaneous perforators). Their mean length was 22.3 ± 8.59 mm
164 (Tables 2 and 4). The posterior branch of the LABCN was vascularized by 1.80 ± 0.92
165 perforators larger than 0.5 mm in diameter originating from the radial artery (Fig. 3): 50%
166 were in the proximal third, 39% in the middle third, and 11% in the distal third (Tables 2 and
167 3). They were equally direct (septocutaneous) or indirect (musculocutaneous) cutaneous
168 perforators (52% and 48%, respectively). Their mean length was 14 ± 9.26 mm.

169 Interestingly, upon reaching the nerve, the arterial perforator divided into multiple
170 branches. These branches coursed towards the division branches of the LABCN and formed
171 the perineural anastomotic network. In each case, we found that these perforator arteries
172 gave rise to the entire length of the intrinsic neurovascular system. Likewise, these branches
173 also consistently gave rise to an extrinsic neurovascular nerve branch. According to
174 Nakajima et al., the LABCN is a radiated type of nerve, which means it divides into several
175 branches to create a fan shape. The LABCN has a Type 2 cutaneous nerve vascularization
176 (extrinsic neurocutaneous vascular system present in one or two branches and not in the
177 others) [9]. Using the Taylor and Ham classification [7], we found that the LABCN has Type
178 C vascularization (source artery provides a segmental blood supply via a long artery
179 coursing on the surface of the nerve). In each dissection, perforator arteries larger >0.5 mm
180 were accompanied by perforator veins. Two venae comitantes were usually found at the
181 origins of the main vessels.

182 In the proximal two-thirds of the forearm where the nerve penetrated the deep fascia
183 and ran superficial to it, most of the perforator arteries vascularized the LABCN and
184 originated from the radial artery (septocutaneous perforator artery in most cases). The distal
185 segmental vascularization of the LABCN seemed to be more connected to the fascial
186 vascular plexus.

187

188 *3.1.3. Neurocutaneous and venous branch from perforator arteries (Fig. 4 and Table 2)*

189 Nutrient arteries of the nerve (neurocutaneous branches) also vascularized the skin in
190 92% of the cases and the cephalic vein in 80% of the specimens. All perforator arteries
191 came from the radial artery (Table 2).

192

193 *3.2. Medial antebrachial cutaneous nerve (MABCN)*

194 *3.2.1. Anatomical characteristics*

195 The MABCN travels down the arm medial to the brachial artery, then pierces the deep fascia
196 with the basilic vein, approximately in the middle of the arm, to become subcutaneous, and
197 runs to the elbow and the forearm. The MABCN provides sensory innervation to the skin of
198 medial forearm (Fig. 5).

199 In all our dissected specimens, the MABCN bifurcated into anterior and posterior
200 branches, proximal to the medial epicondyle (Table 1). The anterior branch crossed the
201 elbow between the medial epicondyle and the biceps tendon, usually in front of the
202 antebrachial basilic vein. It then travelled superficially to the flexor carpi ulnaris (FCU)
203 muscle and ended around 100 mm from the wrist in every dissection. Its mean proximal
204 diameter (1.61 ± 0.29 mm) at the flexion crease of the elbow was similar to the LABCN's
205 diameter. Its length was 189 ± 47 mm. A posterior branch was found in 100% of the
206 specimens dissected. It was medial to the FCU muscle belly and medial to the antebrachial
207 basilic vein. It was smaller than the anterior branch, with a mean diameter of 1.52 ± 0.45 mm
208 and a mean length of 145 ± 38 mm (Table 1). There was a third branch in one specimen,
209 which progressed down the forearm and posterior to the FCU muscle (Tables 4 and 5).

210

211 *3.2.2. MABCN nerve vascularization*

212 The MABCN received several nutrient vessels, provided either by ulnar artery perforators in
213 90% of the specimens or by brachial artery perforators in 10% of the specimens. In 2

214 specimens (17%), vascularization of the posterior branch was provided by the anterior
215 interosseous artery perforator. In the cubital fossa, the perforator arteries directly entered the
216 intrinsic blood supply to all MABCNs and to the anterior and posterior divisions. In total,
217 several segmental vessels entered the MABCN. Six to seven segmental perforator arteries
218 vascularized the MABCN in the forearm; most of them were cutaneous perforator arteries.

219 Regarding the anterior branch of the MABCN, 2 or 3 perforators (mean of 2.42 ± 1.24)
220 larger than 0.5 mm in diameter were mostly located in the proximal (55%) or the middle third
221 (32%) of the forearm. These were either indirect (38%) or direct (62%) cutaneous perforators.
222 The indirect muscular perforators were most frequently located in the proximal third and
223 emerged from the FCU's muscle belly. The direct perforators were found most often in the
224 middle and distal thirds of the forearm. The mean length of the perforators that vascularized
225 the anterior branch of the MABCN was 21.6 ± 11.91 mm (Tables 4 and 5).

226 Regarding the posterior branch of the MABCN, there were 1 to 2 perforators ($1.16 \pm$
227 1.29) larger than 0.5 mm in diameter located mostly in the middle third of the forearm (52%)
228 or in the proximal and distal thirds (28% and 20%, respectively). The perforators were mostly
229 (80%) indirect (musculocutaneous). The mean length of the perforators that vascularized the
230 posterior branch of the MABCN was 14.9 ± 11.91 mm (Tables 4 and 5).

231 Interestingly, upon reaching the nerve, the arterial perforator divided into multiple
232 branches. These branches coursed towards the division branches of the MABCN and
233 formed the perineural anastomotic network. In each specimen, we found that these
234 perforator arteries gave rise to the entire length of the intrinsic neurovascular system and to
235 the extrinsic neurovascular nerve branches like the LABCN did. According to Nakajima et al.,
236 the MABCN is a radiated type of nerve, which means that it divides into several branches to
237 create a fan shape. It also has a Type 2 cutaneous nerve vascularization where the extrinsic
238 neurocutaneous vascular system was present in only one or two branches [9]. According to
239 the Taylor and Ham classification [7], we found that the MABCN had Type C vascularization.

240 This pertains to the source artery providing a segmental blood supply to a long artery that
241 courses on the surface of nerves.

242 In each dissected specimen, perforator arteries larger than 0.5 mm were accompanied
243 by perforator veins. Two venae comitantes were usually found at the origins of the main
244 vessels.

245 In the proximal two-thirds of the forearm where the nerve penetrated the deep fascia
246 and ran superficial to it, most of the perforator arteries vascularized the MABCN and
247 originated from the ulnar artery (in most cases: septocutaneous perforator artery for the
248 anterior division and musculocutaneous perforator artery for the posterior division). The
249 distal segmental vascularization of the MABCN seemed to be more connected to the fascial
250 vascular plexus.

251

252 *3.2.3. Neurocutaneous and venous branch from perforator arteries*

253 Nutrient arteries of the nerve (neurocutaneous branches) also vascularized the skin in 88%
254 of the specimens and the antebrachial basilic vein in 78% of the specimens. All perforator
255 arteries came from the ulnar artery (Fig. 5, Table 4).

256

257 **4. Discussion**

258 The vascular blood supply of nerves has been well studied over the centuries [9,18–21]. In
259 1892, French surgeons Quénu and Lejars were the first to describe the anatomy of the blood
260 supply to the peripheral nerves [22]. Later, breakthroughs in the understanding of peripheral
261 nerve vascularization were credited to Sir Sydney Sunderland, who demonstrated the
262 relationship between source arteries and peripheral nerve vascularization [23]. He stated
263 that the vascularization of the nerve is done by an interconnected vascular network of
264 intrinsic systems (i.e.: intrinsic vascular network) reinforced by segmental extrinsic vessels
265 from source vessels (i.e.: external vascular network) [23]. Based on these anatomical

266 descriptions, the idea that VNGs could be raised including both segmental intrinsic and
267 extrinsic vessels was introduced as a new field of research for nerve reconstruction
268 surgeons [14,24,25]. Taylor and Ham introduced the notion of free VNGs in 1976 on the
269 basis of cadaver and animal studies [7,25]. Then, in 1983, Lebreton et al. showed that the
270 brachial part of the ulnar nerve can be used satisfactorily as a free microsurgical transfer or
271 pedicled on the superior ulnar collateral artery in cases requiring transplantation of a large
272 nerve trunk [20]. Currently, free VNGs have become increasingly popular since they are
273 useful in bridging large nerve gaps if the recipient bed is heavily scarred [26]. Lastly, Bertelli
274 et al. studied the vascularization of the sensory nerves of the forearm in order to describe
275 neurocutaneous axial island flaps in the forearm to cover defects in the distal part of the
276 forearm [11–13]. Based on cadaver and animal studies, they found that the vascularization
277 of the cutaneous nerves is connected with the vascularization of the skin [11].

278 In this anatomical study, we found, like others, that the LABCN and MABCN exhibit the
279 same vascularization with a mean of 8 cutaneous perforator arteries per nerve, all along the
280 forearm (Fig. 6). The source arteries originated from the radial artery for the LABCN or from
281 the ulnar artery for the MABCN. Most were found in the proximal third of the forearm,
282 forming a proximal cluster of perforators. In this cluster, these perforator arteries had a
283 diameter > 0.5 mm and a mean length of almost 30 mm (Fig. 6).

284 Regarding LABCN vascularization, we found in all dissected specimens that a
285 cutaneous perforator artery—the proximal radial perforator artery (also called the inferior
286 cubital artery perforator)—provides branches for nerve and skin vascularization. This artery,
287 first described by Lamberty and Cormack, is a constant artery found in the proximal third of
288 the anterior forearm, with a mean diameter of 1 mm and a mean length of almost 40 mm
289 [27–29]. The origin of this artery is 35 ± 5 mm distal to the midpoint of the interepicondylar
290 line on the anterior aspect of the forearm on the medial side of the brachioradialis muscle
291 [27,29].

292 Regarding the MABCN, we also found a constant proximal ulnar artery perforator with
293 a mean diameter of 1 mm and a mean length of 25 mm in all dissected specimens. This

294 proximal perforator artery was located at the junction between the proximal and middle thirds
295 of the line linking the medial humeral epicondyle and the pisiform in all our specimens, as
296 described by Wei et al. [30].

297 More specifically, we found that these perforator arteries gave rise to two types of
298 arteries that vascularized these nerves, both of which were neurocutaneous arteries. The
299 first type was the intrinsic neurocutaneous artery consisting of the arteries of the epineurium
300 and their branches to the skin. The second was the extrinsic neurocutaneous artery supplied
301 by the cutaneous perforator arteries and their branches to the skin, and the superficial veins.
302 The extrinsic branch can also be called the extrinsic neurocutaneous or neurovenous branch
303 because it gives rise to cutaneous and venous branches. Hence, these anastomotic
304 plexuses vascularize the LABCN and MABCN (intrinsic and extrinsic network), the
305 antebrachial cephalic vein, and the skin. These perforator arteries seem to be predominantly
306 related anatomically with nerves and skin. They were only secondarily associated with the
307 veins because vein perforators were very small (impossible to measure).

308 Taylor et al. and Nakajima et al. also demonstrated that two types of arteries (intrinsic
309 and extrinsic arteries) vascularized the cutaneous nerves of the upper extremity [9,18]. In
310 their cadaver study, Nakajima et al. carefully described all these arterial branches for the
311 superficial nerves. They found that there were many variations in the branching forms of the
312 cutaneous nerves. In their study, all the cutaneous nerves in the extremities had an intrinsic
313 neurovascular system through their entire length, but did not always have the extrinsic
314 neurocutaneous arteries [9]. They also found that there were three different types of
315 cutaneous nerve vascularization, depending on the presence of the extrinsic
316 neurocutaneous vascular system. In Type 1, the extrinsic neurocutaneous vascular system
317 is present along the main nerve trunk over its entire length. In Type 2, the extrinsic
318 neurocutaneous vascular system is present only in one or two branches. In Type 3, the
319 nerves do not have any extrinsic neurocutaneous vascular systems [14,19]. Nakajima et al.
320 classified the LABCN and MABCN as Type 3 nerves [14,19] since they found no extrinsic
321 neurovascular branches in these nerves. The lack of extrinsic neurovascular system is

322 compensated by the accompanying artery of the cutaneous vein running with the nerve. This
323 accompanying artery was common to the nerve and the vein [19]. In all our dissected
324 specimens, we found this accompanying artery (Figs. 4, 6) in both the antebrachial cephalic
325 and basilic veins. We described this artery as an extrinsic neurovascular artery. However,
326 we agree with Nakajima et al. that this artery arose all along the forearm between both the
327 superficial nerves and veins [9]. This means that their vascularity could be hard to dissociate.
328 Consequently, if a potential VNG is raised, both superficial nerves and veins can be used. It
329 is interesting to note that similar results have been published by Doi et al. and Bulla et al.
330 who described the sural and saphenous nerve grafts as having common vascularization with
331 the superficial veins [31,32].

332 Restoring the continuity to a damaged nerve with defect remains challenging for
333 reconstructive surgeons [8]. In some instances, VNGs are mandatory, especially when large
334 nerve gaps in a heavily scarred bed need to be reconstructed; however, the use of VNGs in
335 clinical practice is still controversial [2,7,26,33,34]. There are a few donor VNGs found in the
336 literature: the superficial branch of the radial nerve based on the radial artery, the ulnar
337 nerve based on the superior ulnar collateral artery, the superficial fibular (peroneal) nerve
338 based on the fibular artery, the saphenous nerve based on the saphenous artery, and the
339 sural nerve based on the superficial sural artery [31,32,35–37]. Most of these VNG free flaps
340 were based on large local arterial vessels or arterialized veins with their accompanying vasa
341 nervorum. Very few studies have described the use of perforator arteries and veins as
342 source vessels for VNGs.

343 In 1981, Comtet et al. described a new type of VNG: the medial brachial cutaneous
344 nerve vascularized by an artery arising from the brachial artery [19]. Interestingly, Doi et al.,
345 in 1987, showed in an anatomical and clinical study that a small VNG—the vascularized
346 sural nerve graft—was supplied by the cutaneous perforator of the fibular artery or the
347 muscular perforating branch of the posterior tibial artery [31]. In addition, they showed that
348 the vascularized sural nerve graft could be sectioned into as many as four segments while
349 safely maintaining each segment's vascularity to increase the size of the VNG. A monitoring

350 skin paddle can be raised with the nerve graft because of the conjoint vascularization of the
351 nerve and skin. Although this is an extremely attractive technique, it seems difficult to apply.
352 Hayashida et al. also described the use of a vascularized sural nerve graft on a fibular artery
353 perforator for immediate reconstruction of the inferior alveolar nerve defects. They reported a
354 good clinical result [38]. Finally, Bulla et al. demonstrated that the saphenous nerve is
355 vascularized by an interperforator anastomotic network from the posterior tibial artery
356 network. There was a venous drainage system allowed by the venous perforator in the great
357 saphenous vein (GSV). This perineural anastomotic network vascularized the saphenous
358 nerve, the GSV, and the skin [31]. Taken together, these studies suggest the possibility of
359 using superficial subcutaneous VNGs in the lower extremities.

360 To the best of our knowledge, very few VNG donor sites in the upper extremities have
361 been described [39,40]. Thus, our study focused on forearm sensory cutaneous nerves
362 (LABCN and MABCN). These nerves can be useful donor sites for the reconstruction of
363 nerve defects of the hand, fingers, or upper limbs. If needed in the upper extremities, these
364 VNGs can be helpful because they can be raised in the same surgical sites, for example, for
365 digital neurovascular bundle injury reconstruction. In addition, it has been shown that these
366 nerves are very secure donor nerves with good diameters compared to digital nerves, and
367 they do not exhibit functional morbidity [3–6,41]. Finally, the resulting scar on the ventral side
368 of the forearm is visible but inconspicuous and well protected by the natural positioning of
369 the arm.

370 As we have discussed before, since most of the perforator arteries were found in the
371 proximal third of the forearm, a midline incision of about 30 or 50 mm in the proximal third of
372 the forearm could theoretically allow the surgeon to harvest a VNG of the LABCN or the
373 MABCN. In our anatomical study, we found one perforator artery with these two venous
374 comitantes from the radial and ulnar arteries in each dissected specimen. After dissecting
375 both the nerve and superficial vein, distal to proximal, the pedicle of the VNG could
376 theoretically be found 35 mm distal to the elbow crease. In most of the cases, we found that
377 the pedicle had a diameter >0.5 mm with a length of almost 30 mm. The nerve flap would

378 need to be harvested with the superficial veins to avoid iatrogenic trauma of the
379 accompanying extrinsic artery. Whether the surgeon needs to harvest the antebrachial
380 basilic or the cephalic vein to avoid an extrinsic artery lesion during dissection could not be
381 determined in this study. Since we found that the perforator arteries that vascularized the
382 LABCN and MABCN also vascularized the skin, the surgeon could design a composite flap
383 with vascularized nerve and skin paddle based on the same pedicle (Fig. 7) [15].

384 Two major limitations of this study warrant mention. First, the number of dissections
385 was limited. Second, all measurements were performed manually with a digital caliper.
386 Possible measurement errors could not be avoided. Nevertheless, the consistent results in
387 this small sample and the meticulous measurements taken by the same surgeon decreased
388 the risk of false results. Further clinical studies are needed to analyze the *in vivo* feasibility of
389 this VNG.

390

391 **5. Conclusion**

392 Altogether, this anatomical study shows that reconstructive surgeons can use potential
393 VNGs based on the perforator artery of the forearm, as already described for the
394 vascularized sural nerve graft. The next step would be clinical application of these VNGs in
395 forearm nerve reconstructions.

396

397 **Declaration of conflict of interest:**

398 The authors declare they have no conflict of interest.

399

400 **Funding:**

401 The authors declared no potential conflicts of interest with respect to the research,
402 authorship, and/or publication of this article.

403

404 **References**

405

406 [1] Higgins JP, Fisher S, Serletti JM, Orlando GS. Assessment of nerve graft donor

407 sites used for reconstruction of traumatic digital nerve defects. *J Hand Surg Am*

408 2002;27:286–92.

409 [2] Mackinnon SE, Kelly L, Hunter DA. Comparison of regeneration across a

410 vascularized versus conventional nerve graft: case report. *Microsurgery* 1988;9:226–34.

411 [3] Pilanci O, Ozel A, Basaran K, Celikdelen A, Berkoz O, Saydam FA, et al. Is there a

412 profit to use the lateral antebrachial cutaneous nerve as a graft source in digital nerve

413 reconstruction? *Microsurgery* 2014;34:367–71.

414 [4] Nunley JA, Ugino MR, Goldner RD, Regan N, Urbaniak JR. Use of the anterior

415 branch of the medial antebrachial cutaneous nerve as a graft for the repair of defects of the

416 digital nerve. *J Bone Joint Surg Am* 1989;71:563–7.

417 [5] Unal MB, Gokkus K, Sirin E, Cansü E. Lateral antebrachial cutaneous nerve as a

418 donor source for digital nerve grafting: A concept revisited. *Open Orthop J* 2017;11:1041–8.

419 [6] Mackinnon SE, Dellon AL. The overlap pattern of the lateral antebrachial cutaneous

420 nerve and the superficial branch of the radial nerve. *J Hand Surg Am* 1985;10:522–6.

421 [7] Taylor GI, Ham FJ. The free vascularized nerve graft. A further experimental and

422 clinical application of microvascular techniques. *Plast Reconstr Surg* 1976;57:413–26.

423 [8] Tubbs RS, Rizk E, Shoja MM, Loukas M, Barbaro N, Spinner RJ. Nerves and nerve

424 injuries: Vol 1: History, Embryology, anatomy, imaging, and diagnostics. Cambridge, MA,

425 Academic Press; 2015.

426 [9] Nakajima H, Imanishi N, Fukuzumi S, Minabe T, Aiso S, Fujino T. Accompanying

427 arteries of the cutaneous veins and cutaneous nerves in the extremities: anatomical study

428 and a concept of the venoadipofascial and/or neuroadipofascial pedicled fasciocutaneous

429 flap. *Plast Reconstr Surg* 1998;102:779–91.

430 [10] Masquelet AC, Romana MC, Wolf G. Skin island flaps supplied by the vascular axis

431 of the sensitive superficial nerves: anatomic study and clinical experience in the leg. *Plast*

432 *Reconstr Surg* 1992;89:1115–21..

- 433 [11] Bertelli JA, Kaleli T. Retrograde-flow neurocutaneous island flaps in the forearm:
434 anatomic basis and clinical results. *Plast Reconstr Surg* 1995;95:851–9.
- 435 [12] Bertelli JA. Neurocutaneous axial island flaps in the forearm: anatomical,
436 experimental and preliminary clinical results. *Br J Plast Surg* 1993;46:489–96.
- 437 [13] Bertelli J, Khoury Z. Vascularization of lateral and medial cutaneous nerves of the
438 forearm. Anatomic basis of neuro-cutaneous island flap on the elbow. *Surg Radiol Anat*
439 1991;13:345–6.
- 440 [14] Taylor GI. Free vascularized nerve transfer in the upper extremity. *Hand Clin*
441 1999;15:673–95, ix–x.
- 442 [15] Camuzard O, Foissac R, Baqué P, Bronsard N, Georgiou C. The vascularized
443 lateral antebrachial cutaneous nerve graft based on a radial artery perforator for nerve defect
444 reconstruction: An anatomical study. *Plast Reconstr Surg* 2016;137:256e–7e.
- 445 [16] Boorman JG, Sykes PJ. Vascularised versus conventional nerve grafting: a case
446 report. *J Hand Surg Br* 1987;12:218–20.
- 447 [17] Peng TH, Ding HM, Chen SH, Tang ML, Hong L, Tan JG, et al. Demonstration of
448 three injection methods for the analysis of extrinsic and intrinsic blood supply of the
449 peripheral nerve. *Surg Radiol Anat* 2009;31:567–71.
- 450 [18] Hong MKH, Hong MKY, Taylor GI. Angiosome territories of the nerves of the upper
451 limbs. *Plast Reconstr Surg* 2006;118:148–60.
- 452 [19] Comtet JJ. The use of cutaneous nerves as vascularized grafts. *Ann Chir Main*
453 1989;8:313–5 [in French].
- 454 [20] Lebreton E, Bourgeon Y, Lascombes P, Merle M, Foucher G. Systemization of the
455 vascularization of the ulnar nerve in its upper arm. *Ann Chir Main* 1983;2:211–8.
- 456 [21] Lundborg G. The intrinsic vascularization of human peripheral nerves: structural and
457 functional aspects. *J Hand Surg Am* 1979;4:34–41.
- 458 [22] Quenu E, Lejars FM. Etude anatomique sur les vaisseaux sanguins des nerfs. *Arch*
459 *Neurol* 1892;23:1, n.d.
- 460 [23] Sunderland SS. *Nerves and nerve injuries*. Edinburgh, Livingstone, 1978.

- 461 [24] Taylor GI, Gianoutsos MP, Morris SF. The neurovascular territories of the skin and
462 muscles: anatomic study and clinical implications. *Plast Reconstr Surg* 1994;94:1–36.
- 463 [25] Taylor GI, Palmer JH. The vascular territories (angiosomes) of the body:
464 experimental study and clinical applications. *Br J Plast Surg* 1987;40:113–41.
- 465 [26] Zhu Y, Liu S, Zhou S, Yu Z, Tian Z, Zhang C, et al. Vascularized versus
466 nonvascularized facial nerve grafts using a new rabbit model. *Plast Reconstr Surg*
467 2015;135:331e–9e.
- 468 [27] Lamberty BG, Cormack GC. The forearm angiotomes. *Br J Plast Surg* 1982;35:420–
469 9.
- 470 [28] Lamberty BG, Cormack GC. The antecubital fascio-cutaneous flap. *Br J Plast Surg*
471 1983;36:428–33.
- 472 [29] Camuzard O, Foissac R, Clerico C, Fernandez J, Balaguer T, Ihrai T, et al. Inferior
473 cubital artery perforator flap for soft-tissue coverage of the elbow: Anatomical study and
474 clinical application. *J Bone Joint Surg Am* 2016;98:457–65.
- 475 [30] Wei Y, Shi X, Yu Y, Zhong G, Tang M, Mei J. Vascular anatomy and clinical
476 application of the free proximal ulnar artery perforator flaps. *Plast Reconstr Surg Glob Open*
477 2014;2:e179.
- 478 [31] Bulla A, Bolletta A, Fiorot L, Maffei M, Bandiera P, Casoli V, et al. Posterior tibial
479 perforators relationship with superficial nerves and veins: A cadaver study. *Microsurgery*
480 2019;39:241–6.
- 481 [32] Doi K, Kuwata N, Kawakami F, Tamaru K, Kawai S. The free vascularized sural
482 nerve graft. *Microsurgery* 1984;5:175–84.
- 483 [33] el-Barrany WG, Marei AG, Vallée B. Anatomic basis of vascularised nerve grafts:
484 the blood supply of peripheral nerves. *Surg Radiol Anat* 1999;21:95–102.
- 485 [34] Iwai M, Tamai S, Yajima H, Kawanishi K. Experimental study of vascularized nerve
486 graft: evaluation of nerve regeneration using choline acetyltransferase activity. *Microsurgery*
487 2001;21:43–51.
- 488 [35] el-Khatib HA. Island fasciocutaneous flap based on the proximal perforators of the

489 radial artery for resurfacing of burned cubital fossa. *Plast Reconstr Surg* 1997;100:919–25.

490 [36] Macionis V. A pedicled vascularized ulnar nerve graft based on the epineurial
491 vascular supply: a case report. *J Reconstr Microsurg* 2008;24:453–5.

492 [37] Merle M, Dautel G. Vascularised nerve grafts. *J Hand Surg Br* 1991;16:483–8.

493 [38] Hayashida K, Hiroto S, Morooka S, Kuwabara K, Fujioka M. The vascularized sural
494 nerve graft based on a peroneal artery perforator for reconstruction of the inferior alveolar
495 nerve defect. *Microsurgery* 2015;35:244–8.

496 [39] Zhang FH, Topp SG, Zhang WJ, Zheng HP, Zhang F. Anatomic study of distally
497 based pedicle compound flaps with nutrient vessels of the cutaneous nerves and superficial
498 veins of the forearm. *Microsurgery* 2006;26:373–85.

499 [40] Wang S, Luo S, Hao X. The superficial vein, cutaneous nerve and its nutrient
500 vessels in the forearm: anatomic study and the clinical implication. *Zhonghua Zheng Xing*
501 *Wai Ke Za Zhi* 2000;16:212–5 [in Chinese].

502 [41] Chevrollier J, Pedeutour B, Dap F, Dautel G. Evaluation of emergency nerve grafting
503 for proper palmar digital nerve defects: a retrospective single centre study. *Orthop Traumatol*
504 *Surg Res* 2014;100:605–10.

505

506

507

508

509

510 **Figure legends**

511 Fig. 1. Proximal-to-distal axis passing through the midpoint of the distal palmar flexion
512 crease of the wrist and the midpoint of the elbow crease.

513 Fig. 2. Anterior branch of the lateral antebrachial cutaneous nerve and perforator arteries
514 from the radial artery. *White arrowheads*: radial artery; *arrows*: perforator arteries; *white*
515 *stars*: LAbN; *black arrowheads*: neuro-cutaneous or neuro-venous vascularization.

516 Fig. 3. Posterior branch of the lateral antebrachial cutaneous nerve and perforator arteries
517 from the radial artery. *White arrowheads*: radial artery; *arrows*: radial artery perforator; *white*
518 *stars*: LAbN; *black arrowheads*: neuro-cutaneous or neuro-venous vascularization.

519 Fig. 4. Forearm dissection showing the proximal perforator of the radial artery.

520 Consistent proximal perforator of the radial artery (*PRAP*) with the cutaneous or
521 neurocutaneous branch (*black stars*), arterial extrinsic neurovascular system in their entire
522 length (*white stars*) of the lateral antebrachial cutaneous nerve (LABCN). *RA*: radial artery;
523 *ABCV*: antebrachial cephalic vein, *LF*: lacertus fibrosus

524 Fig. 5. Anterior branch of the medial antebrachial cutaneous nerve and perforator arteries
525 originating from the ulnar artery. *White arrowheads and in red*: ulnar artery (*UA*); *arrows*:
526 ulnar artery perforator; *white stars and in yellow*: medial antebrachial cutaneous nerve
527 (*MABCN*); *black arrowheads*: neuro-cutaneous arterial branch.

528 Fig. 6. Distribution of perforator arteries > 0.5mm that vascularized the lateral and medial
529 antebrachial cutaneous nerve. LABCN: lateral antebrachial cutaneous nerve; MABCN:
530 medial antebrachial cutaneous nerve; *RA*: radial artery; *UA*: ulnar artery

531 Fig. 7. Design of composite flaps combining a sensory superficial nerve, a superficial vein
532 and a skin paddle vascularized by a cutaneous perforator artery. *PAP*: Proximal artery
533 perforator with the cutaneous branch and two commitment perforator veins; *N*: nerve; *CV*:
534 cephalic vein

535

536 **Table titles**

537 Table 1. General characteristics of the lateral and medial antebrachial cutaneous nerves

538 *: Proximal diameter when piercing the deep fascia in the elbow area; **: distal diameter of
539 the main anterior branch of LABCN and MABCN; *SD*: standard deviation

540 Table 2. Characteristics of the lateral antebrachial cutaneous nerve's (LABCN)

541 vascularization. *a*: anterior branch of the *LABCN*; *p*: posterior branch of the *LABCN*; *Vp*:
542 common branch from the perforator artery for vascularization of superficial vein; *Cp*:
543 common vascularization with the skin (neurocutaneous branch); *SD*: standard deviation

544 Table 3. Location and characteristics of perforator arteries with a diameter > 0.5 mm that
545 vascularize the lateral antebrachial cutaneous nerve (LABCN). *a*: anterior branch of the
546 LABCN; *p*: posterior branch of the LABCN; *SD*: standard deviation

547 Table 4. Characteristics of the medial antebrachial cutaneous nerve's (MABCN)

548 vascularization. *a*: anterior branch of the MABCN; *p*: posterior branch of the MABCN; *Vp*:
549 common branch from the perforator artery for vascularization of superficial vein; *Cp*:
550 common vascularization with the skin (neurocutaneous branch); *SD*: standard deviation

551 Table 5. Location and characteristics of perforator arteries with a diameter > 0.5 mm that
552 vascularize the medial antebrachial cutaneous nerve (MABCN). *a*: anterior branch of the
553 MABCN; *p*: posterior branch of the MABCN; *SD*: standard deviation

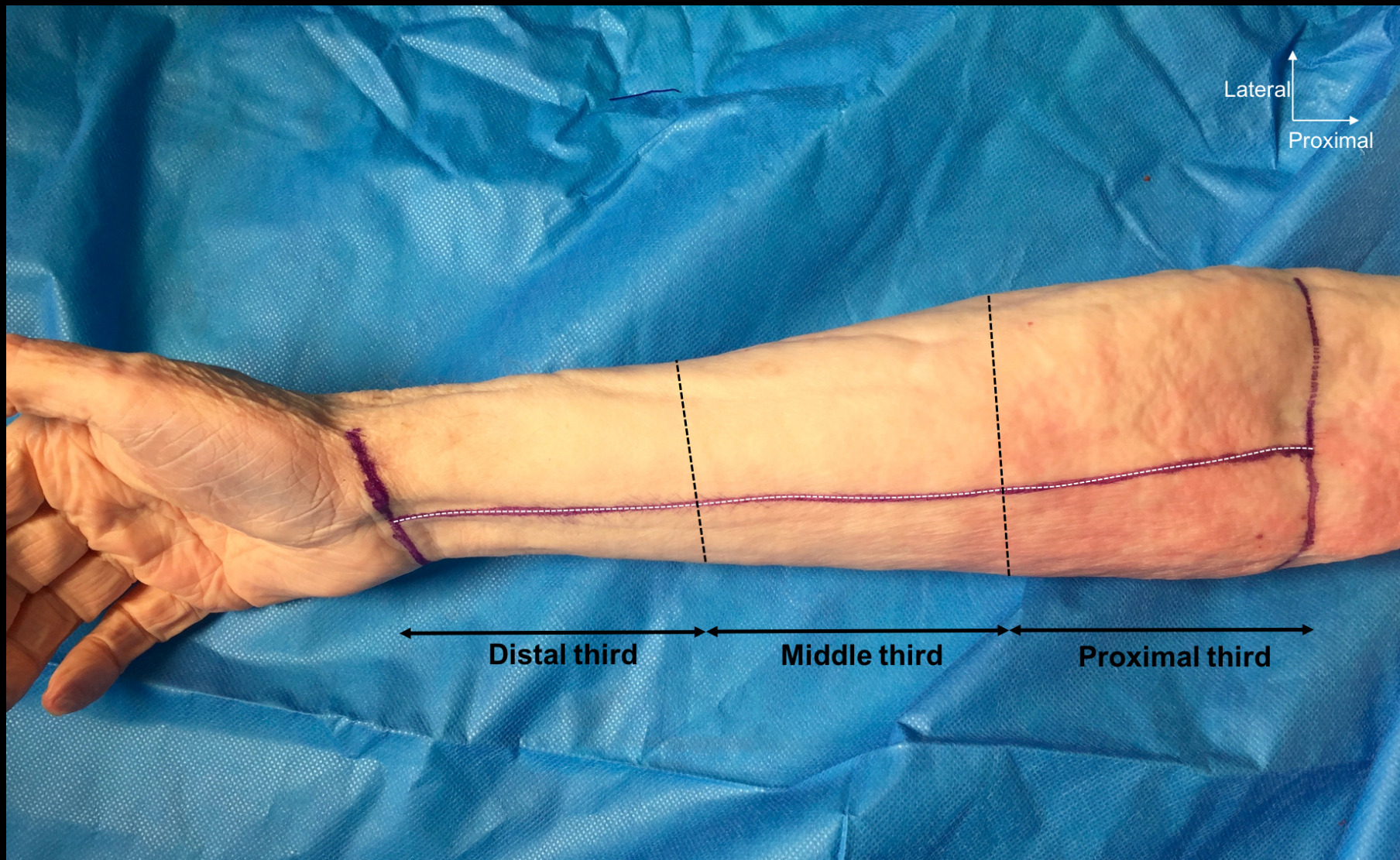


FIGURE 1

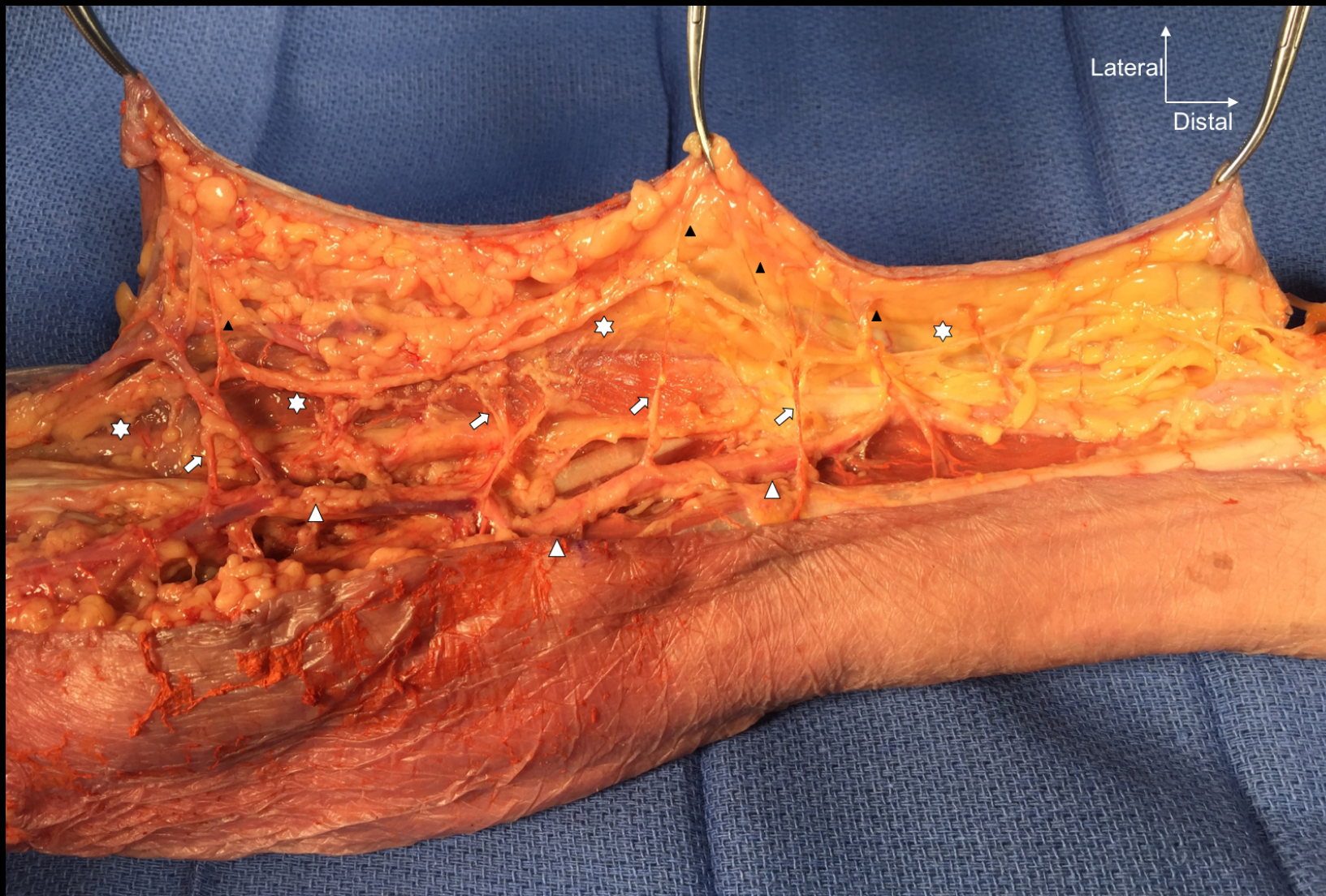

FIGURE 2

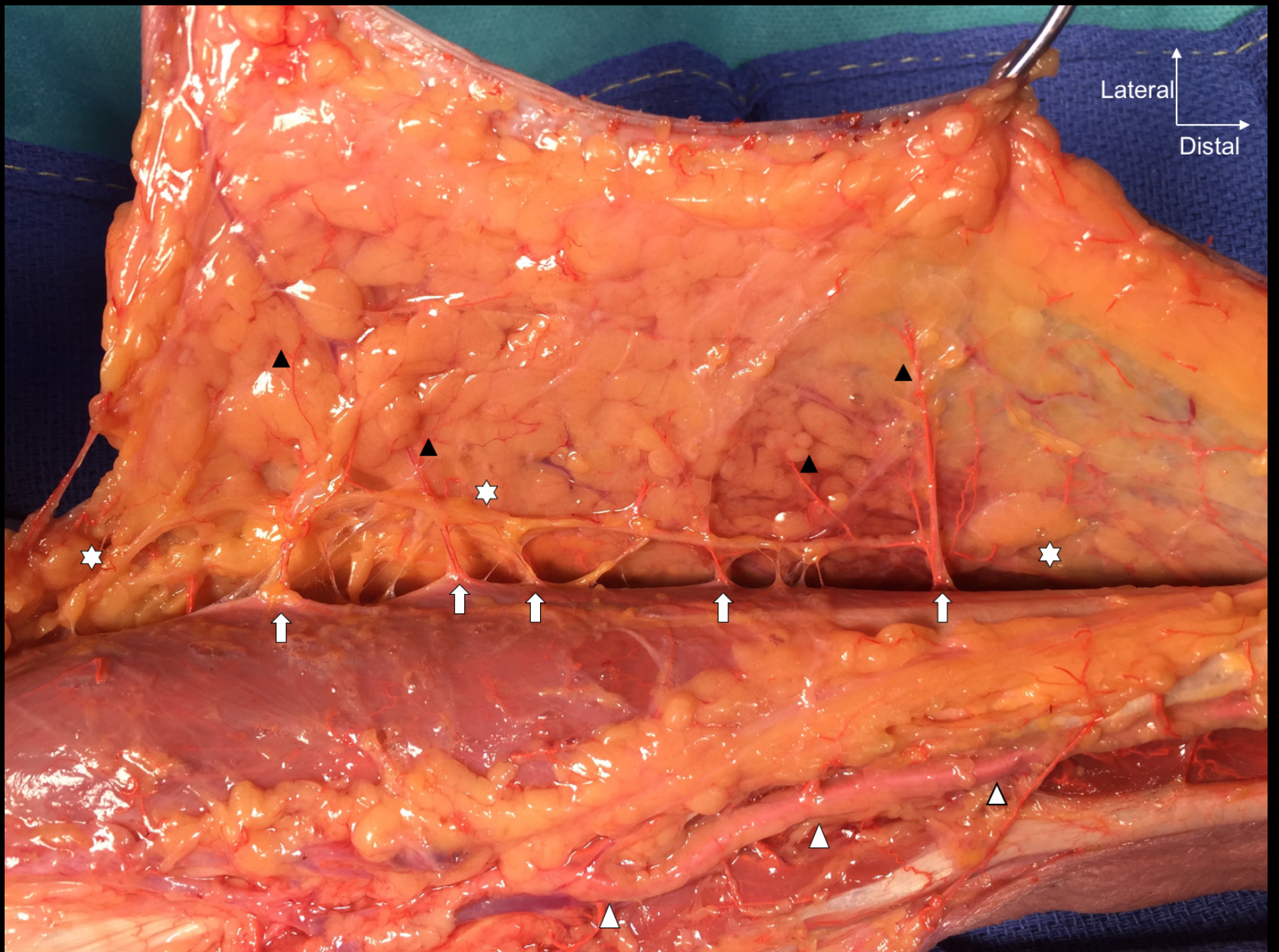


FIGURE 3

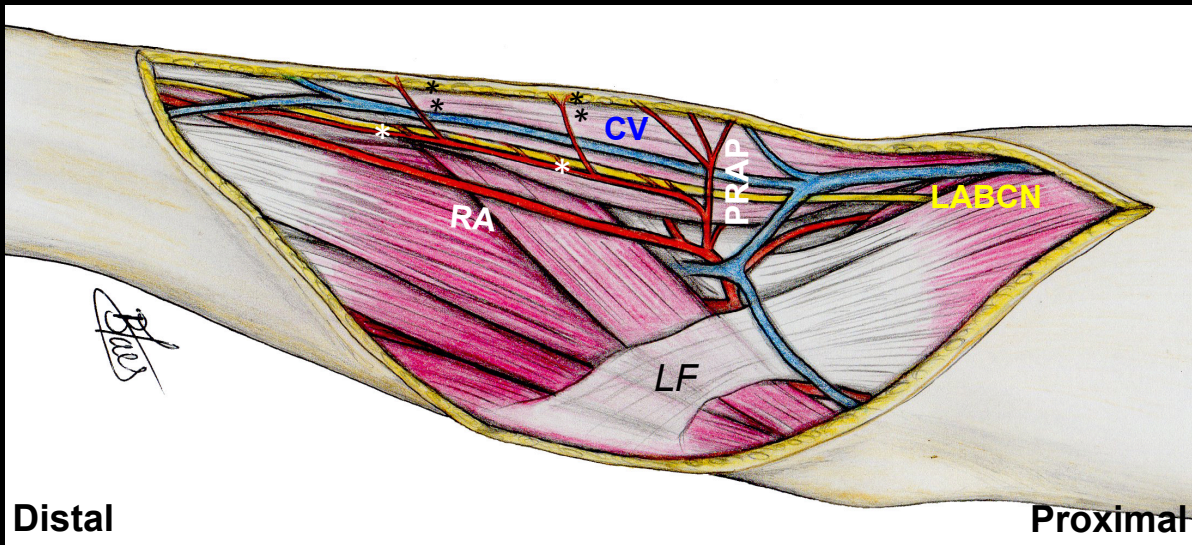
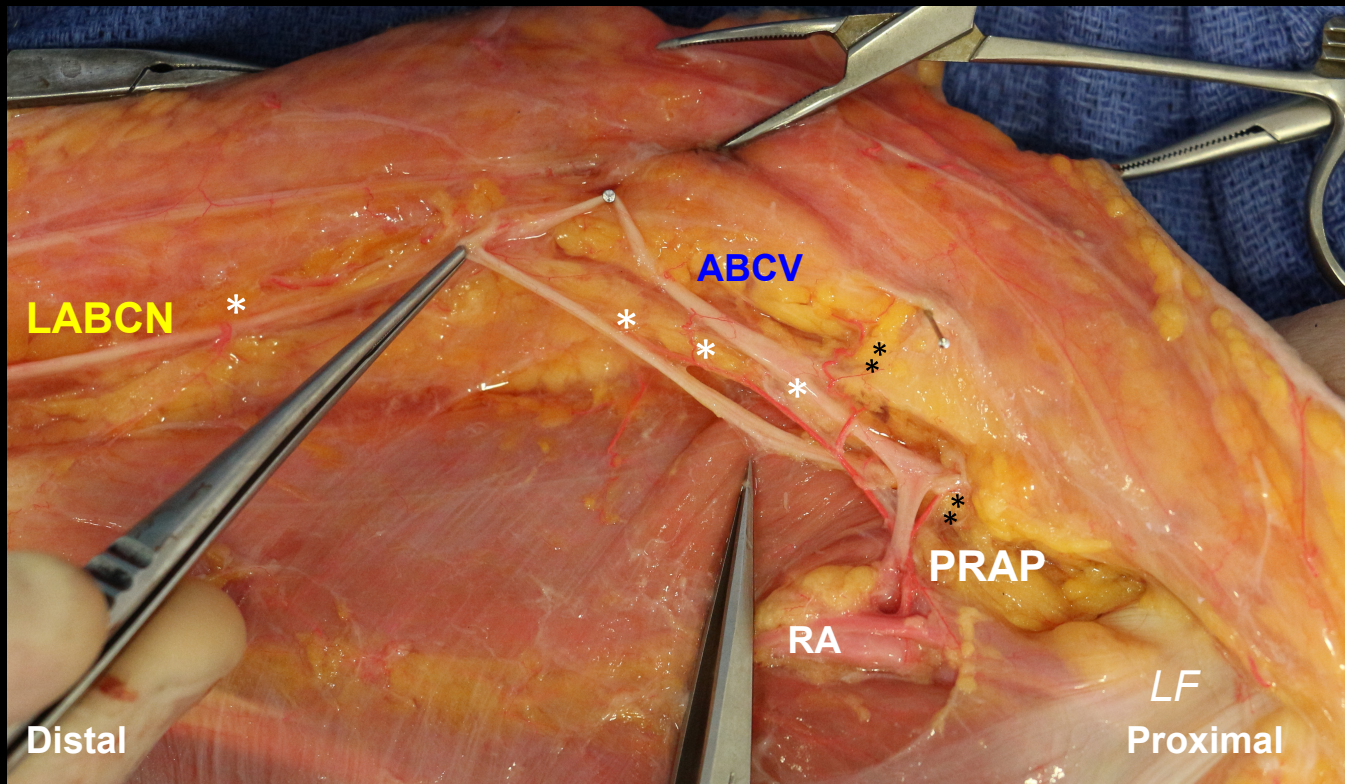


FIGURE 4

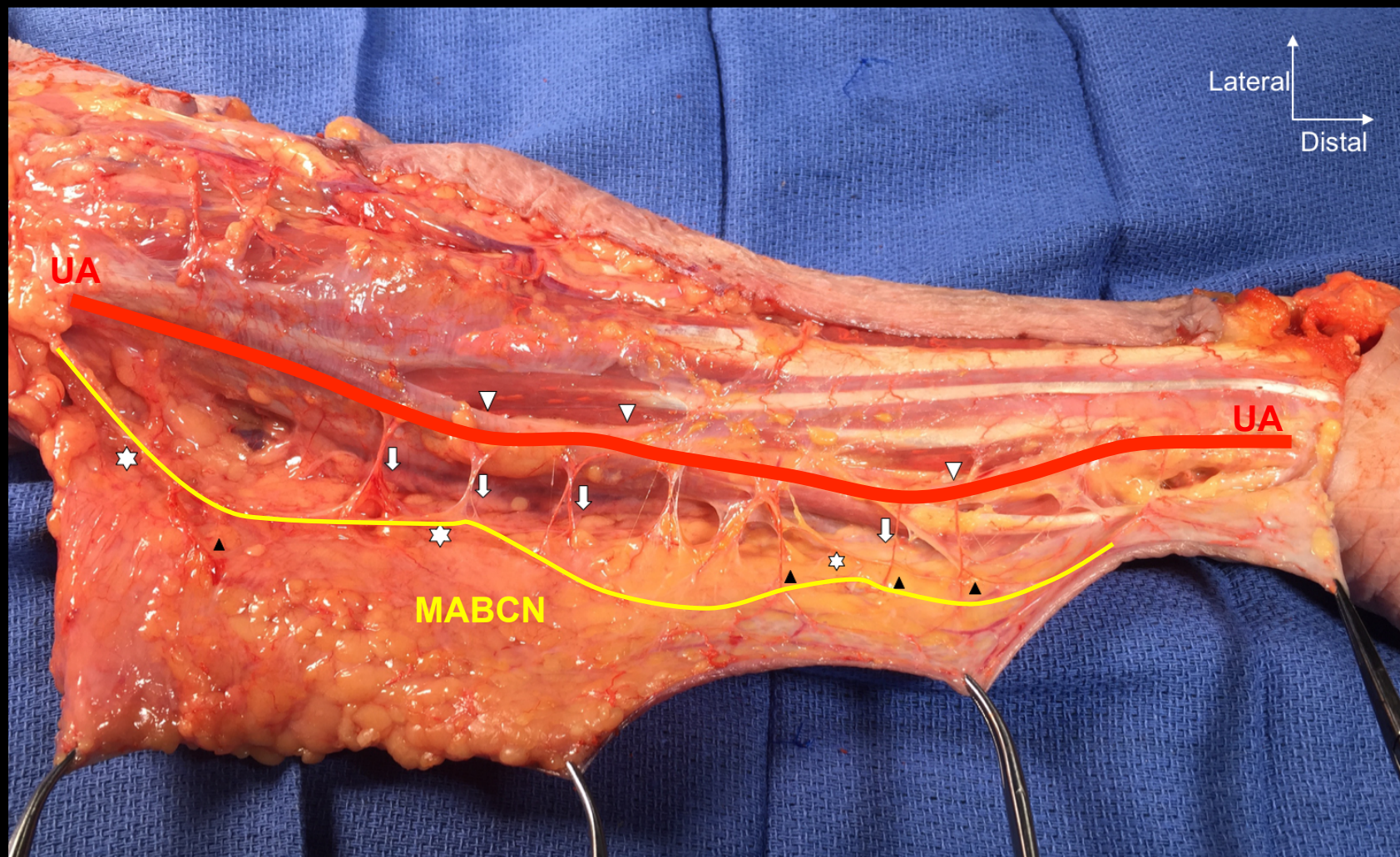
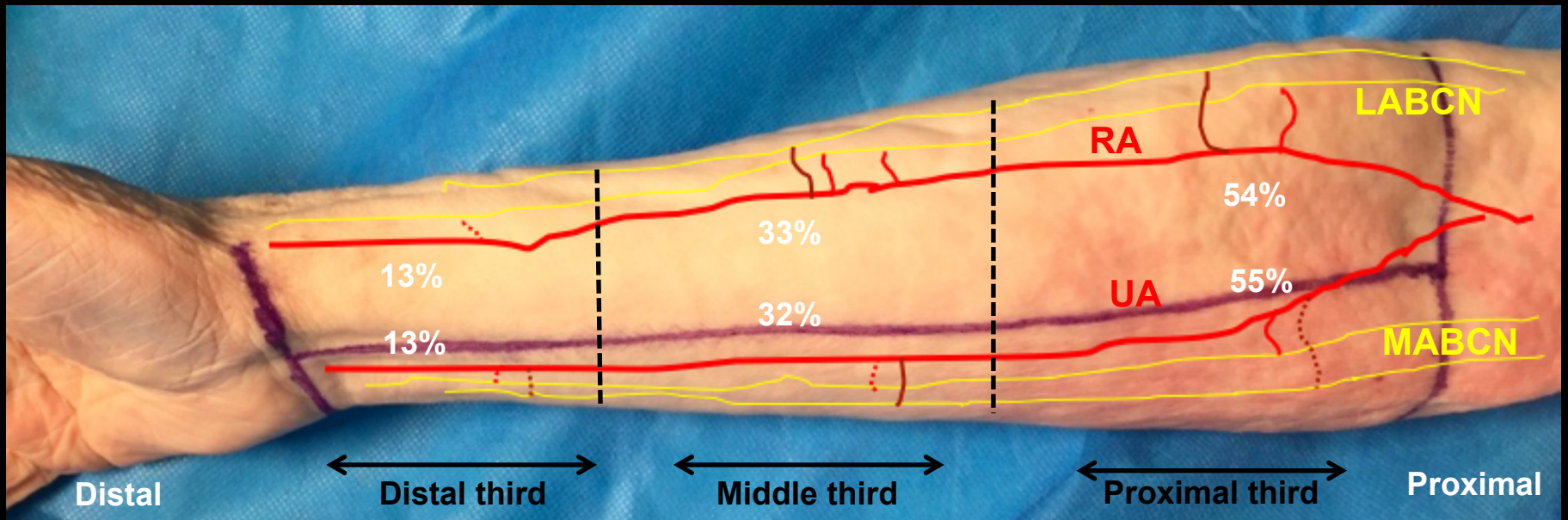


FIGURE 5



- Direct perforator artery (septocutaneous)
- - - Indirect perforator artery (musculocutaneous)
- Superficial cutaneous nerve

FIGURE 6

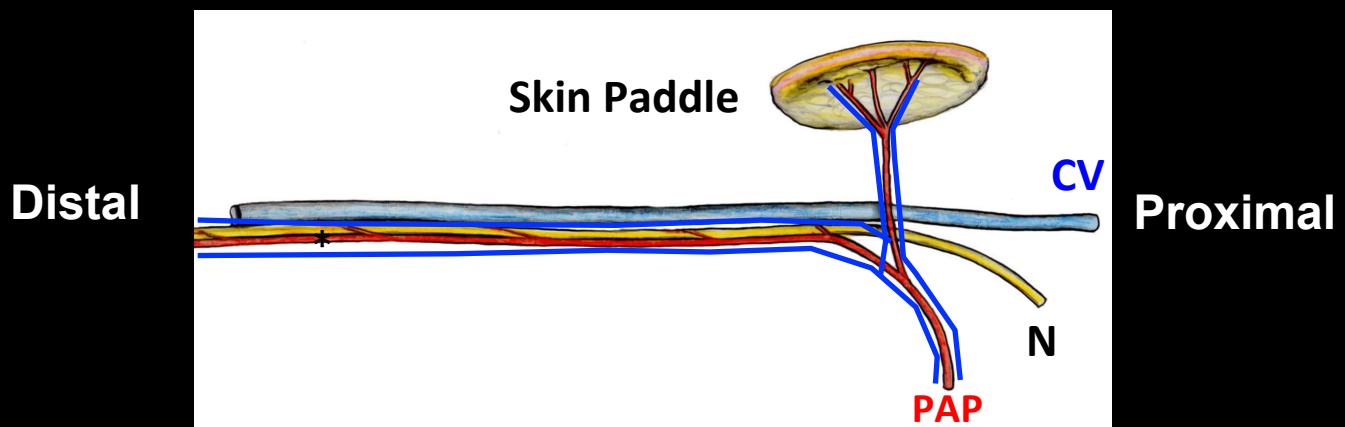


FIGURE 7

Specimen	lateral antebrachial cutaneous nerve (LABCN)			medial antebrachial cutaneous nerve (MABCN)		
	Number of terminal branches	Proximal nerve diameter (mm)*	Distal nerve diameter (mm)**	Number of terminal branches	Proximal nerve diameter (mm)*	Distal nerve diameter (mm)**
1	3	1.9	1.6	2	1.5	1.2
2	3	1.6	1.4	2	1.6	1.2
3	2	1.5	1.4	2	1.5	1.3
4	1	1.4	1.1	2	1.9	1.6
5	2	1.9	1.5	2	1.7	1.5
6	2	1.8	1.4	2	1.6	0.8
7	2	2.5	1.8	2	1.1	0.9
8	2	1.5	1.3	2	1.6	1.5
9	2	1.4	1.2	2	1.8	1.5
10	2	1.4	1.1	2	1.5	1.1
11	2	1.9	1.5	2	1.9	1.5
12	3	1.1	0.9	2	1.6	1.4
Mean	2.17	1.66	1.35	2	1.61	1.29
SD	0.58	0.37	0.25	-	0.29	0.27

Table 1. General characteristics of the lateral and medial antebrachial cutaneous nerves

*: Proximal diameter when piercing the deep fascia in the elbow area; **: distal diameter of the main anterior branch of LACN and MACN; *SD*: standard deviation

Specimen	Total number of radial perforator arteries vascularizing the LABCN branches		Total number of perforator arteries (> 0.5 mm) vascularizing the LABCN branches		Mean length of perforator artery (> 0.5 mm) vascularizing the LABCN branches (mm)		Presence of Vp (%)	Presence of Cp (%)
	aLABCN	pLABCN	aLABCN	pLABCN	aLABCN	pLABCN		
1	9	2	2	1	23	20	80	100
2	9	4	4	2	21	15	83	89
3	9	3	5	2	11	7	83	92
4	10	1	5	0	13	-	60	80
5	7	7	3	0	34	-	71	93
6	6	4	4	2	31	33	80	91
7	10	5	3	2	29	8	80	92
8	8	3	4	3	22	7	73	91
9	8	4	2	2	12	12	83	90
10	6	3	3	1	32	13	80	100
11	8	8	5	0	16	-	94	88
12	8	5	4	3	24	19	96	93
Mean	8.2	4.4	3.7	1.8	22.3	14	80	92
SD	1.4	1.8	1.1	0.9	8.1	8.6	9.6	5.2

Table 2. Characteristics of the lateral antebrachial cutaneous nerve's (LABCN)

vascularization. *a*: anterior branch of the *LABCN*; *p*: posterior branch of the *LABCN*; *Vp*:

common branch from the perforator artery for vascularization of superficial vein; *Cp*: common

vascularization with the skin (neurocutaneous branch); *SD*: standard deviation

Specimen	Proximal third of the forearm				Middle third of the forearm				Distal third of the forearm				Number of musculo-cutaneous perforators				Number of septo-cutaneous perforators			
	aLABCN		pLABCN		aLABCN		pLABCN		aLABCN		pLABCN		aLABCN		pLABCN		aLABCN		pLABCN	
	n	%	n	%	n	%	n	%	n	%	n	%	n	%	n	%	n	%	n	%
1	1	50	1	100	1	50	0	-	0	-	0	-	2	22	1	50	7	78	1	50
2	1	25	0	-	1	25	0	-	2	50	2	100	2	22	1	25	7	78	3	75
3	1	20	1	50	1	20	1	50	3	60	0	-	1	11	1	33	8	89	2	63
5	3	100	0	-	0	-	0	-	0	-	0	-	2	28	2	29	5	78	5	71
6	2	50	0	-	2	50	2	100	0	-	0	-	1	16	1	33	4	84	3	84
7	2	67	2	1	1	33	0	-	0	-	0	-	3	30	2	33	7	70	3	70
8	4	100	2	67	0	33	1	33	0	-	0	-	3	37	1	33	5	63	2	64
9	2	100	0	-	0	-	2	100	0	-	0	-	0	0	2	50	8	100	2	50
10	1	50	1	100	1	50	0	-	0	-	0	-	1	16	2	67	5	84	2	33
11	2	40	0	-	3	60	0	-	0	-	0	-	2	25	3	37	6	75	5	63
12	3	75	1	33	1	25	2	67	0	-	0	-	1	12	2	40	7	88	3	60
Mean	2	52	1	50	1	35	0.89	39	0.58	13	0.22	11	1.83	15	1.44	48	3	85	1.11	52
SD	1.07	30	0.76	43	0.98	27	0.93	42	1.08	23	0.67	33	1.11	11	0.52	50	1.35	30	1.05	50

Table 3. Location and characteristics of perforator arteries with a diameter > 0.5 mm that vascularize the lateral antebrachial cutaneous nerve (LABCN). *aLABCN*: anterior branch of the LABCN; *pLABCN*: posterior branch of the LABCN; *SD*: standard deviation

Specimen	Total number of perforator arteries vascularizing the MABCN branches		Total number of perforator arteries (> 0.5 mm) vascularizing the MABCN branches		Mean length of perforator artery (> 0.5 mm) vascularizing the MABCN branches (mm)		Presence of Vp (%)	Presence of Cp (%)
	aMABCN	pMABCN	aMABCN	pMABCN	aMABCN	pMABCN		
1	7	7	4	4	18	16	87	100
2	3	3	0	0	-	-	75	75
3	8	4	2	1	16	10	75	93
4	5	3	2	0	33	-	66	83
5	5	5	3	2	25	20	63	91
6	14	4	2	2	29	27	79	95
7	7	2	1	0	17	-	80	90
8	7	3	2	2	8	4,5	90	72
9	5	2	3	0	26	-	83	83
10	5	4	2	0	27	-	67	83
11	9	4	4	3	15	12	78	93
12	6	3	4	0	23.5	-	60	86
Mean	6.75	3.67	2.42	1.16	21.59	14.91	78	88
SD	2.8	1.57	1.24	1.29	7.92	11.91	9.2	7.7

Table 4. Characteristics of the medial antebrachial cutaneous nerve's (MABCN)

vascularization. *aMABCN*: anterior branch of the MABCN; *pMABCN*: posterior branch of the MABCN; *Vp*: common branch from the perforator artery for vascularization of superficial vein; *Cp*: common vascularization with the skin (neurocutaneous branch); *SD*: standard deviation

Specimen	Proximal third of the forearm				Middle third of the forearm				Distal third of the forearm				Number of musculo-cutaneous perforators				Number of septo-cutaneous perforators			
	aMABCN		pMABCN		aMABCN		pMABCN		aMABCN		pMABCN		aMABCN		pMABCN		aMABCN		pMABCN	
	n	%	n	%	n	%	n	%	n	%	n	%	n	%	n	%	n	%	n	%
1	1	25	1	25	1	25	1	25	2	50	2	50	4	57	4	57	3	43	3	43
2	-	-	-	-	-	-	-	-	-	-	-	-	1	33	0	0	2	77	0	0
3	1	50	-	-	1	50	1	100	-	-	-	-	3	38	1	25	4	62	3	75
4	2	100	-	-	-	-	-	-	-	-	-	-	2	40	0	0	3	60	0	0
5	2	67	-	-	1	33	2	100	-	-	-	-	2	40	2	40	3	60	3	60
6	1	50	1	50	-	-	1	50	1	50	-	-	4	28	2	50	10	72	2	50
7	1	100	-	-	-	-	-	-	-	-	-	-	4	57	1	50	3	43	1	50
8	-	-	-	-	1	50	1	50	1	50	1	50	3	43	1	33	4	57	2	67
9	1	33	-	-	2	67	-	-	-	-	-	-	1	20	0	0	4	80	0	0
10	1	50	-	-	1	50	-	-	-	-	-	-	2	40	0	0	3	60	0	0
11	3	75	2	67	1	25	1	33	-	-	-	-	2	22	1	25	7	78	3	75
12	2	50	-	-	2	50	-	-	-	-	-	-	2	33	0	0	4	67	0	0
Mean	1.36	55	0.8	28	0.91	32	1	52	0.36	13	0.6	20	1.27	38	2.2	80	1.36	62	0.2	20
SD	0.81	30	0.84	27	0.7	24	0	29	0.67	23	0.89	27	1.27	12.6	1.5	45	1.36	45	0.45	41

Table 5. Location and characteristics of perforator arteries with a diameter > 0.5 mm that vascularize the medial antebrachial cutaneous nerve (MABCN). *aMABCN*: anterior branch of the MABCN; *pMABCN*: posterior branch of the MABCN; *SD*: standard deviation