



HAL
open science

Detection of alpha-synuclein aggregates in gastrointestinal biopsies by protein misfolding cyclic amplification

Alexis Fenyi, Laurène Leclair-Visonneau, Thomas Clairembault, Emmanuel Coron, Michel Neunlist, Ronald Melki, Pascal Derkinderen, Luc Bousset

► To cite this version:

Alexis Fenyi, Laurène Leclair-Visonneau, Thomas Clairembault, Emmanuel Coron, Michel Neunlist, et al.. Detection of alpha-synuclein aggregates in gastrointestinal biopsies by protein misfolding cyclic amplification. *Neurobiology of Disease*, 2019, 129, pp.38-43. 10.1016/j.nbd.2019.05.002 . cea-02279266

HAL Id: cea-02279266

<https://cea.hal.science/cea-02279266>

Submitted on 22 Oct 2021

HAL is a multi-disciplinary open access archive for the deposit and dissemination of scientific research documents, whether they are published or not. The documents may come from teaching and research institutions in France or abroad, or from public or private research centers.

L'archive ouverte pluridisciplinaire **HAL**, est destinée au dépôt et à la diffusion de documents scientifiques de niveau recherche, publiés ou non, émanant des établissements d'enseignement et de recherche français ou étrangers, des laboratoires publics ou privés.



Distributed under a Creative Commons Attribution - NonCommercial 4.0 International License

1 **Detection of alpha-synuclein aggregates in gastrointestinal biopsies by**
2 **Protein Misfolding Cyclic Amplification**

3 Alexis Fenyi¹, Laurène Leclair-Visonneau^{2,3}, Thomas Clairembault², Emmanuel Coron^{2,3},
4 Michel Neunlist^{2,3}, Ronald Melki¹, Pascal Derkinderen^{2,3,4} and Luc Bousset¹

5 ¹Institut Fancois Jacob (MIRcen), CEA and Laboratory of Neurodegenerative Diseases, CNRS,
6 18 Route du Panorama, 92265 Fontenay-Aux-Roses cedex, France.

7 ²Inserm, U1235, Faculté de Médecine, 1 rue Gaston Veil, F-44035 Nantes, France

8 ³University Nantes, Faculté de Médecine, 1 rue Gaston Veil, F-44035 Nantes, France

9 ⁴CHU Nantes, Department of Neurology, Nantes, Bd Jacques Monod, F-44093 Nantes, France

10 **Author Email Addresses:**

11 Alexis Fenyi (alexis.fenyi@cnr.fr)

12 Ronald Melki (ronald.melki@cnr.fr)

13 Laurène Leclair-Visonneau (laurene.leclair@chu-nantes.fr)

14 Thomas Clairembault (clairembault.thomas@gmail.com)

15 Emmanuel Coron (emmanuel.coron@chu-nantes.fr)

16 Michel Neunlist (michel.neunlist@univ-nantes.fr)

17 Pascal Derkinderen (derkinderenp@yahoo.fr)

18 Luc Bousset (luc.bousset@cnr.fr)

19 **Corresponding authors:**

20 Dr Luc Bousset: Institut Fancois Jacob (MIRcen), CEA and Laboratory of Neurodegenerative
21 Diseases, CNRS, 18 Route du Panorama, 92265 Fontenay-Aux-Roses cedex, France.

22 luc.bousset@cnr.fr;

23 Dr Pascal Derkinderen: Inserm, U1235, Faculté de Médecine, 1 rue Gaston Veil, F-44035
24 Nantes, France ; pascal.derkinderen@chu-nantes.fr, derkinderenp@yahoo.fr

25 **Abstract**

26 Lewy bodies and neurites, the pathological signatures found in the central nervous
27 system of Parkinson's disease (PD) patients, are primarily composed of aggregated alpha-
28 synuclein (aSyn). The observation that aSyn aggregates are also found in the enteric nervous
29 system has prompted several studies aimed at developing a diagnostic procedure based on
30 the detection of pathological aSyn in gastrointestinal (GI) biopsies. The existing studies,
31 which have all used immunohistochemistry for the detection of pathological aSyn, have had
32 conflicting results. In the current survey, we analyzed the seeding propensity of aSyn
33 aggregates from GI biopsies.

34 A total of 29 subjects participated to this study, 18 PD patients and 11 controls. For
35 each patient, 2 to 4 GI biopsies were taken from the same site (antrum, sigmoid colon or
36 rectum) and used to seed the aggregation of recombinant aSyn in an assay inspired from the
37 Protein Misfolding Cyclic Amplification (PMCA) method. In a subset of patients and controls
38 (14 and 3, respectively), one or two additional biopsies were analyzed by
39 immunohistochemistry for the presence of phosphorylated aSyn histopathology (PASH)
40 using antibodies against phosphorylated aSyn and PGP 9.5.

41 Except for one subject, none of the control samples seeded aSyn aggregation in
42 PMCA reaction. GI biopsies from patients with PD seeded aSyn aggregation in 10 out of 18
43 cases (7 from the sigmoid colon, 2 from the antrum and one from the rectum). There was
44 good agreement between PMCA and immunohistochemistry results as, except for two cases,
45 all PMCA-positive PD patients were also PASH-positive.

46 Our findings show that the PMCA method we implemented is capable of detecting
47 aSyn aggregates in routine GI biopsies. They also suggest that rectum biopsies do not
48 contain sufficient amounts of aggregated aSyn to detect seeded assembly by PMCA. While

49 encouraging, our findings indicate that further studies are needed to establish the diagnostic
50 potential of the PMCA method we implemented to detect aSyn aggregates in upper GI
51 biopsies.

52 **Keywords**

53 Alpha-synuclein; Parkinson's disease; Protein Misfolding Cyclic Amplification; gut; enteric
54 nervous system; biopsy

55 **List of abbreviations**

56 aSyn – alpha-synuclein

57 CNS – central nervous system

58 CSF – cerebrospinal fluid

59 ENS – enteric nervous system

60 FFPE – Formalin-fixed, paraffin-embedded

61 GI – gastrointestinal

62 PASH – phosphorylated aSyn histopathology

63 PD -Parkinson's disease

64 PGP9.5 -Protein Gene Product 9.5

65 PMCA – Protein Misfolding Cyclic Amplification

66 ThT - Thioflavine T

67 **Introduction**

68 The *postmortem* detection by immunohistochemistry of aggregated alpha-synuclein
69 (aSyn) in the brain along with neuronal loss in the *substantia nigra* remain the gold standard
70 for the definite diagnosis of Parkinson's disease (PD). Over the last 12 years, several studies
71 have shown that aSyn aggregates can also be detected outside the central nervous system,
72 particularly in the enteric nervous system (ENS) [1–4]. The ENS is a neuronal network

73 embedded in the lining of the gastrointestinal (GI) tract from the lower third of the
74 esophagus to the rectum, whose distinguishing feature is its accessibility and suitability for
75 routine GI biopsies [5]. These findings logically prompted a substantial amount of research
76 to determine if the immunohistochemical detection of pathological aSyn in routine GI
77 biopsies could be used for pathological diagnosis of PD within patients lifespan (reviewed in
78 [6,7]).

79 In our seminal study, using microdissection and whole-mount preparation of colonic
80 biopsies, we detected aSyn pathology in 21 out of 29 PD patients and in none of the controls
81 [8]. Although the microdissection technique we have developed provides outstanding
82 information on the morphology of enteric neurons, it nonetheless has several limitations as
83 it needs to be performed immediately after the endoscopic procedure and requires technical
84 expertise and training [5]. Most subsequent studies on GI biopsies in PD have therefore been
85 performed on formalin-fixed, paraffin-embedded (FFPE) tissue, which has the main
86 advantages of being readily accessible to most hospital-based laboratories and to allow
87 retrospective analyses. Nevertheless, the diagnostic utility of FFPE GI biopsies in PD remains
88 unclear, as these studies yielded conflicting results regarding the sensitivity and specificity of
89 GI biopsies in detecting pathological aSyn [9–17].

90 One possible explanation for the observed discrepancies between existing studies on
91 immunohistochemical detection of aSyn pathology in the ENS is the very low amount of aSyn
92 aggregates usually found in GI samples. Protein Misfolding Cyclic Amplification (PMCA)
93 enables ultrasensitive detection of the pathogenic prion protein PrP in Creutzfeldt-Jakob
94 disease through amplification of its misfolding and aggregation *in vitro* under different
95 experimental conditions [18]. This technique has been recently used to detect aggregated
96 aSyn in the CSF of PD patients [19] and in formaldehyde-fixed samples from multiple system

97 atrophy patients [20]. We implemented this method to assess the presence of pathogenic
98 aSyn in GI biopsies.

99 **Methods**

100 *Subjects, GI biopsies and study design*

101 A total of 29 subjects participated to this study, 18 patients with PD and 11 controls. PD
102 patients who were diagnosed according to the United Kingdom PD Society Brain Bank
103 criteria were recruited from the movement disorder clinic at Nantes University Hospital,
104 France. 16 out of 18 PD patients had a rectosigmoidoscopy or a colonoscopy, while the
105 remaining 2 had upper GI endoscopy for placement of an administration tube for continuous
106 levodopa enteral infusion. As controls, we used GI biopsies from 2 groups : (1) 7 subjects
107 who had colonoscopy for colorectal cancer screening, (2) 4 subjects with Crohn's disease
108 who underwent either rectosigmoidoscopy or colonoscopy for disease management and
109 surveillance (Table 1). All control subjects had a detailed neurological examination to rule
110 out PD symptoms and cognitive deficiency. Two to 4 biopsies per subject were snap frozen
111 in liquid nitrogen at the time of collection and stored at -80°C. 14 PD cases and 3 control
112 cases had additional biopsies (taken from the same site, either in the sigmoid colon [2
113 biopsies] or in the rectum [1 biopsy]) that were analyzed by immunohistochemistry (see
114 below). The study protocol was approved by the local Committee on Ethics and Human
115 Research (*Comité de Protection des Personnes Ouest IV and VI*), conformed to the Code of
116 Ethics of the World Medical Association (Declaration of Helsinki) and was registered on
117 ClinicalTrials.gov (identifier NCT01353183 and NCT01748409). Written informed consent
118 was obtained from each patient and from each control.

119 *Reagents and chemicals*

120 Unless otherwise stated all reagents were purchased from Sigma (Saint-Quentin-Fallavier,
121 France).

122 *Microdissection and immunohistochemistry*

123 Microdissection was performed as previously described in one biopsy (when taken in the
124 rectum) or two biopsies (when taken in the sigmoid colon) [6]. Each whole-mount
125 preparation of submucosa obtained from a single biopsy was permeabilized for 3 hours in
126 phosphate buffered saline (PBS)/NaN₃ containing 1% (v/v) Triton X-100 and 10% (v/v) horse
127 serum and then incubated with antibodies against phosphorylated aSyn (1:5,000, WAKO,
128 Osaka, Japan) and PGP9.5 (1:10,000; Ultraclone Limited, UK). A patient was noted as positive
129 (phosphorylated aSyn histopathology, PASH+) when at least one structure immunoreactive
130 for both phosphorylated aSyn and PGP9.5 was observed.

131 *Biopsies treatment for amplification*

132 2 to 4 Biopsies were weighted in a Safelock 2mL Biopur tube (Eppendorf, Montesson,
133 France). The biopsies were resuspended 5% (weight: volume) in buffer (150mM KCl, 50mM
134 Tris-HCl pH7.5) and disrupted by sonication using a Branson SFX 150 Cell Disruptor sonicator
135 equipped with a 3.17mm microtip probe (Emerson, Bron, France). Sonication was applied for
136 10 seconds at 70% of the maximum amplitude. The resulting homogenate was aliquoted and
137 flash frozen in liquid nitrogen before storage at -80°C.

138 *PMCA assay*

139 Biopsies homogenates were diluted in 150mM KCl, 50mM Tris-HCl pH7.5 to a final
140 proportion of 2% (weight: volume). Monomeric aSyn concentration was adjusted to 100µM
141 in a total volume of 300µL. The solution was split in 2 replicates in a PCR strips (BIOplastics,
142 Landgraaf, The Netherlands) tubes (150µl in each). PMCA amplification was performed on 2
143 replicates for each patient using the Q700 generator and a 431MPX horn (both from

144 Qsonica, Fisher scientific, Illkirch, France). The power of the horn was set to 30% of the
145 maximum amplitude. The sonication protocol consisted of 15sec of sonication and 315sec of
146 rest at 31°C. Every hour, 5 μ L from each tube were collected and diluted into 300 μ L
147 Thioflavine T (ThT, 10 μ M). The amplification was monitored by measuring ThT fluorescence
148 increase using a Cary Eclipse Fluorescence Spectrophotometer (Agilent, les Ulis, France) with
149 fixed excitation and emission wavelength at 440 and 480nm, respectively. The sensitivity of
150 the method was assessed using recombinant preformed fibrils. The detection threshold was
151 determined to be in the range of 10 pM of aggregated aSyn (Figure 1). PMCA efficacy was
152 derived from the lag phase length and was considered high when the lag phase was shorter
153 or equal to 300 minutes and was considered medium to low when it lied within the time
154 frame 300 to 425 minutes. Statistical analysis were performed using ANOVA, on the duration
155 of the lag phase or the ThT fluorecence at 480 minutes (Figure 2 C and D).

156 **Results**

157 A total of 29 subjects participated to this study, 18 PD patients (12 males, mean age \pm
158 standard deviation: 63.7 \pm 7.7 years) and 11 controls (7 males, 52.4 \pm 15.3 years). Age and sex
159 did not differ significantly between patients and controls (Table 1).

160 Two to 4 biopsies were obtained from each PD cases and control cases. For each
161 subject multiple biopsies were pooled and homogenized as follow: 2 pooled biopsies for 6
162 PD cases, 3 pooled biopsies for 3 PD cases and 3 controls, 4 pooled biopsies for 9 PD cases
163 and 8 controls (Table 1). Homogenates were blindly analyzed by means of PMCA (Figure 2).
164 Except for subject #1, none of the GI biopsies homogenates from the control group,
165 regardless of the biopsy site (sigmoid colon or rectum), seeded the aggregation of
166 monomeric aSyn. Subject #28 was initially enrolled in 2008 as a control and as such had no
167 signs or symptoms suggestive of PD. She underwent upper GI endoscopy for the

168 investigation of anemia and 4 antrum biopsies were taken and stored as part of our research
169 protocol. Because of the positive PMCA result, we decided to clinically reevaluate this
170 patient 10 years after GI biopsies collection. Neurological examination showed that she had
171 developed in the meantime typical signs and symptoms of PD, including right bradykinesia
172 and mild bilateral rest tremor.

173 GI biopsies homogenates from patients with PD seeded monomeric aSyn aggregation
174 in 10 out of 18 cases (Table 1). Among these PMCA+ biopsies, 2 sets of biopsies were taken
175 from the antrum, 7 sets of biopsies were taken in the sigmoid colon while the remaining one
176 was from the rectum. Of note rectal biopsies from 3 out of 4 PD patients yielded negative
177 results with PMCA. Identical results were observed for the rectal biopsies from control
178 patients (Table 1).

179 In 14 patients with PD and 3 controls, one or two additional biopsies were
180 immunohistochemically assessed for the presence of PASH (Figure 3). All 3 controls as well
181 as the 4 PD patients who had rectal biopsies were PASH- (Table 1). When sigmoid biopsies
182 were analyzed, 5 out of 10 PD patients were PASH+ and among these 5 cases, 4 were also
183 PMCA+ (Table 1).

184 **Discussion**

185 Here, we have used GI biopsies from PD patients to show that aSyn aggregates from
186 peripheral autonomic nervous system can be amplified through PMCA. Only one control
187 biopsy induced aSyn aggregation suggesting that the seeding method we implemented has a
188 high specificity. Regarding PD, 2/2 upper GI biopsies, 7/12 sigmoid biopsies and only 1/4
189 rectal biopsies were PMCA+. Although our sample size is too small to draw firm conclusions,
190 our findings are in line with previous reports that showed a rostro-caudal distribution of
191 aSyn pathology in the gut, with the lower esophagus and stomach having the highest

192 frequency of PASH, followed by small bowel regions, colon and rectum [2,21,22]. They also
193 suggest that rectal biopsies are not suited for PMCA-based PD diagnosis. There was
194 significant agreement between PMCA and immunohistochemistry as 4 out of 5 PASH+ PD
195 patients were also PMCA+. Samples from the remaining PMCA+ patients were either not
196 assessed by immunohistochemistry (4 cases) or were PMCA+ but PASH- (2 cases). All PMCA+
197 and PASH+ samples originated from the sigmoid colon (4 cases). Limited agreement
198 between PMCA and immunohistochemistry was observed for rectal samples as none was
199 PASH+ while 1 out of 4 was PMCA+. The same figure was observed for control samples.
200 Altogether, our results suggest that rectal biopsies are not suited for PMCA-based PD
201 diagnosis.

202 An interesting observation is the positive detection of aSyn aggregates in GI samples
203 initially collected as controls from one subject who subsequently developed clinical
204 symptoms of PD (subject #28). In a recent report that used aSyn PMCA in CSF, Shahnawaz *et*
205 *al.* identified two subjects originally enrolled as controls who were subsequently diagnosed
206 as having PD 1 and 4 years after sample collection [19]. These findings suggest that PMCA
207 might be used as a preclinical or premotor diagnostic method for PD.

208 In conclusion, our preliminary study supports the idea that PMCA could be used to
209 detect aSyn aggregates in GI biopsies from PD patients. Further studies are needed to
210 establish the diagnostic potential of PMCA to detect aSyn aggregates in GI biopsies
211 especially in the upper GI tract.

212 **Declarations**

213 *Ethics approval and consent to participate*

214 Regarding sigmoid biopsies sampling, the study protocol was approved by the local
215 Committee on Ethics and Human Research (*Comité de Protection des Personnes Ouest IV and*

216 VI) and was registered on ClinicalTrials.gov (identifier NCT01353183 and NCT01748409).

217 Written informed consent was obtained from each patient and from each control.

218 *Consent for publication*

219 Not applicable.

220 *Availability of data and materials*

221 The datasets used and/or analysed during the current study available from the
222 corresponding author on reasonable request.

223 *Competing interests*

224 None.

225 *Funding*

226 This work was supported by a grant from Fondation NRJ-Institut de France to PD. This
227 project has received funding from the European Union's Horizon 2020 research and
228 innovation programme under grant agreement No. 116060 (IMPRiND). This work is
229 supported by the Swiss State Secretariat for Education, Research and Innovation (SERI)
230 under contract number 17.00038. The opinions expressed and arguments employed herein
231 do not necessarily reflect the official views of these funding bodies. We thank IMAGIF facility
232 for access to Electron Microscopes. LB and RM were supported by Equipe FRM (Fondation
233 pour la Recherche Médicale) 2016 (DEQ2016033489) and the Fondation Simone et Cino Del
234 Duca of the Institut de France.

235 *Author Contributions*

236 AF, RM, TC, PD and LB performed the experiments and analyzed the data. LLV and MN
237 managed the biobanking and dissected the colonic samples. EC performed the endoscopy.
238 AF, RM, PD and LB designed the research and wrote the manuscript.

239 **References**

- 240 1. Braak H, de Vos RAI, Bohl J, Del Tredici K. Gastric alpha-synuclein immunoreactive
241 inclusions in Meissner's and Auerbach's plexuses in cases staged for Parkinson's disease-
242 related brain pathology. *Neurosci Lett*. 2006;396:67–72.
- 243 2. Beach TG, Adler CH, Sue LI, Vedders L, Lue L, White Iii CL, et al. Multi-organ distribution of
244 phosphorylated alpha-synuclein histopathology in subjects with Lewy body disorders. *Acta*
245 *Neuropathol*. 2010;119:689–702.
- 246 3. Bloch A, Probst A, Bissig H, Adams H, Tolnay M. Alpha-synuclein pathology of the spinal
247 and peripheral autonomic nervous system in neurologically unimpaired elderly subjects.
248 *Neuropathol Appl Neurobiol*. 2006;32:284–95.
- 249 4. Gelpi E, Navarro-Otano J, Tolosa E, Gaig C, Compta Y, Rey MJ, et al. Multiple organ
250 involvement by alpha-synuclein pathology in Lewy body disorders. *Mov Disord*.
251 2014;29:1010–8.
- 252 5. Lebouvier T, Coron E, Chaumette T, Paillusson S, Bruley des Varannes S, Neunlist M, et al.
253 Routine colonic biopsies as a new tool to study the enteric nervous system in living patients.
254 *Neurogastroenterol Motil*. 2010;22:e11-14.
- 255 6. Corbillé A-G, Clairembault T, Coron E, Leclair-Visonneau L, Preterre C, Neunlist M, et al.
256 What a gastrointestinal biopsy can tell us about Parkinson's disease? *Neurogastroenterol*
257 *Motil*. 2016;28:966–74.
- 258 7. Schneider SA, Boettner M, Alexoudi A, Zorenkov D, Deuschl G, Wedel T. Can we use
259 peripheral tissue biopsies to diagnose Parkinson's disease? A review of the literature. *Eur J*
260 *Neurol*. 2016;23:247–61.
- 261 8. Lebouvier T, Neunlist M, Bruley des Varannes S, Coron E, Drouard A, N'Guyen J-M, et al.
262 Colonic biopsies to assess the neuropathology of Parkinson's disease and its relationship
263 with symptoms. *PLoS ONE*. 2010;5:e12728.
- 264 9. Shannon KM, Keshavarzian A, Mutlu E, Dodiya HB, Daian D, Jaglin JA, et al. Alpha-
265 synuclein in colonic submucosa in early untreated Parkinson's disease. *Mov Disord*.
266 2012;27:709–15.
- 267 10. Chung SJ, Kim J, Lee HJ, Ryu H-S, Kim K, Lee JH, et al. Alpha-synuclein in gastric and
268 colonic mucosa in Parkinson's disease: Limited role as a biomarker. *Mov Disord*.
269 2016;31:241–9.
- 270 11. Stokholm MG, Iranzo A, Østergaard K, Serradell M, Otto M, Svendsen KB, et al.
271 Assessment of neuroinflammation in patients with idiopathic rapid-eye-movement sleep
272 behaviour disorder: a case-control study. *Lancet Neurol*. 2017;16:789–96.
- 273 12. Antunes L, Frasquilho S, Ostaszewski M, Weber J, Longhino L, Antony P, et al. Similar α -
274 Synuclein staining in the colon mucosa in patients with Parkinson's disease and controls.
275 *Mov Disord*. 2016;31:1567–70.

- 276 13. Barrenschee M, Zorenkov D, Böttner M, Lange C, Cossais F, Scharf AB, et al. Distinct
277 pattern of enteric phospho-alpha-synuclein aggregates and gene expression profiles in
278 patients with Parkinson's disease. *Acta Neuropathol Commun.* 2017;5:1.
- 279 14. Visanji NP, Marras C, Kern DS, Al Dakheel A, Gao A, Liu LWC, et al. Colonic mucosal a-
280 synuclein lacks specificity as a biomarker for Parkinson disease. *Neurology.* 2015;84:609–
281 16.
- 282 15. Hilton D, Stephens M, Kirk L, Edwards P, Potter R, Zajicek J, et al. Accumulation of α -
283 synuclein in the bowel of patients in the pre-clinical phase of Parkinson's disease. *Acta*
284 *Neuropathol.* 2014;127:235–41.
- 285 16. Sánchez-Ferro Á, Rábano A, Catalán MJ, Rodríguez-Valcárcel FC, Fernández Díez S,
286 Herreros-Rodríguez J, et al. In vivo gastric detection of α -synuclein inclusions in Parkinson's
287 disease. *Mov Disord.* 2015;30:517–24.
- 288 17. Corbillé A-G, Letournel F, Kordower JH, Lee J, Shanes E, Neunlist M, et al. Evaluation of
289 alpha-synuclein immunohistochemical methods for the detection of Lewy-type
290 synucleinopathy in gastrointestinal biopsies. *Acta Neuropathol Commun.* 2016;4:35.
- 291 18. Saborio GP, Permanne B, Soto C. Sensitive detection of pathological prion protein by
292 cyclic amplification of protein misfolding. *Nature.* 2001;411:810–3.
- 293 19. Shahnawaz M, Tokuda T, Waragai M, Mendez N, Ishii R, Trenkwalder C, et al.
294 Development of a Biochemical Diagnosis of Parkinson Disease by Detection of α -Synuclein
295 Misfolded Aggregates in Cerebrospinal Fluid. *JAMA Neurol.* 2017;74:163–72.
- 296 20. Becker K, Wang X, Vander Stel K, Chu Y, Kordower J, Ma J. Detecting Alpha Synuclein
297 Seeding Activity in Formaldehyde-Fixed MSA Patient Tissue by PMCA. *Mol Neurobiol.*
298 2018;55:8728–37.
- 299 21. Pouclet H, Lebouvier T, Coron E, des Varannes SB, Rouaud T, Roy M, et al. A comparison
300 between rectal and colonic biopsies to detect Lewy pathology in Parkinson's disease.
301 *Neurobiol Dis.* 2012;45:305–9.
- 302 22. Wakabayashi K, Takahashi H, Takeda S, Ohama E, Ikuta F. Parkinson's disease: the
303 presence of Lewy bodies in Auerbach's and Meissner's plexuses. *Acta Neuropathol.*
304 1988;76:217–21.
- 305
- 306
- 307
- 308
- 309
- 310
- 311

312
313
314
315
316

317 **Legends to Figures**

318 **Figure 1: PMCA of preformed recombinant aSyn fibrils.** Increasing concentration of
319 recombinant seeds were added in the reaction to assess the sensitivity of the PMCA method
320 we implemented. The fluorescence due to the seeds is indicated at time -30 minutes
321 corresponding to the mixing of seeds and monomeric substrate for 1 μ M, 10 μ M and, as a
322 dashed line, for 100 μ M of aSyn fibrils. Time zero corresponds to the time where PMCA
323 amplification is initiated. The concentrations of recombinants fibrils are expressed as initial
324 monomeric concentration. The curves represent the average of 4 replicates +/- SD.

325

326 **Figure 2: PMCA assay in controls and PD.** PMCA was performed using gastrointestinal
327 biopsies homogenates from controls (A) or PD patients (B). aSyn seeded assembly reactions
328 obtained in the presence of homogenates from rectum colon biopsies are coloured in blue
329 (controls) and orange (PD patients). Those obtained in the presence of sigmoid colon
330 biopsies homogenates are coloured in purple (controls) and red (PD patients). Those
331 obtained in the presence of antrum biopsies homogenates are coloured in brown (PD
332 patients). PMCA efficacy was considered high when the assembly kinetics lied within the
333 grey surface area. PMCA efficacy was considered medium or low when the assembly kinetics
334 lied within the hatched grey surface area. The curves represent an average of 2 replicates,
335 +/- SD. (C) Box plot representation of the distribution of ThT fluorescence at time 480 min,
336 (D) Distribution of the lag phase duration. One-way analysis of variance (ANOVA) test was
337 used for statistical analysis; * : P<0.05.

338

339 **Figure 3. Representative photomicrographs of phosphorylated alpha-synuclein and PGP**
340 **9.5 staining in the submucosa of PD patients and controls.** Sigmoid biopsies from one PD
341 patient (PD, #22; upper panels) and one control (CTL, #10; lower panels) were
342 microdissected and analyzed by immunohistochemistry with antibodies against PGP 9.5 and
343 phosphorylated alpha-synuclein (P-aSyn). The representative photomicrographs from PD

344 patient show multiple PASH in whole-mount of submucosa immunoreactive for
345 PGP9.5 (green) that were also positive for P-aSyn (red) in PD. By contrast, no
346 immunoreactivity for P-aSyn was observed in control, with the exception of some faint
347 nonspecific background labeling. Scale bar: 75 μ m.

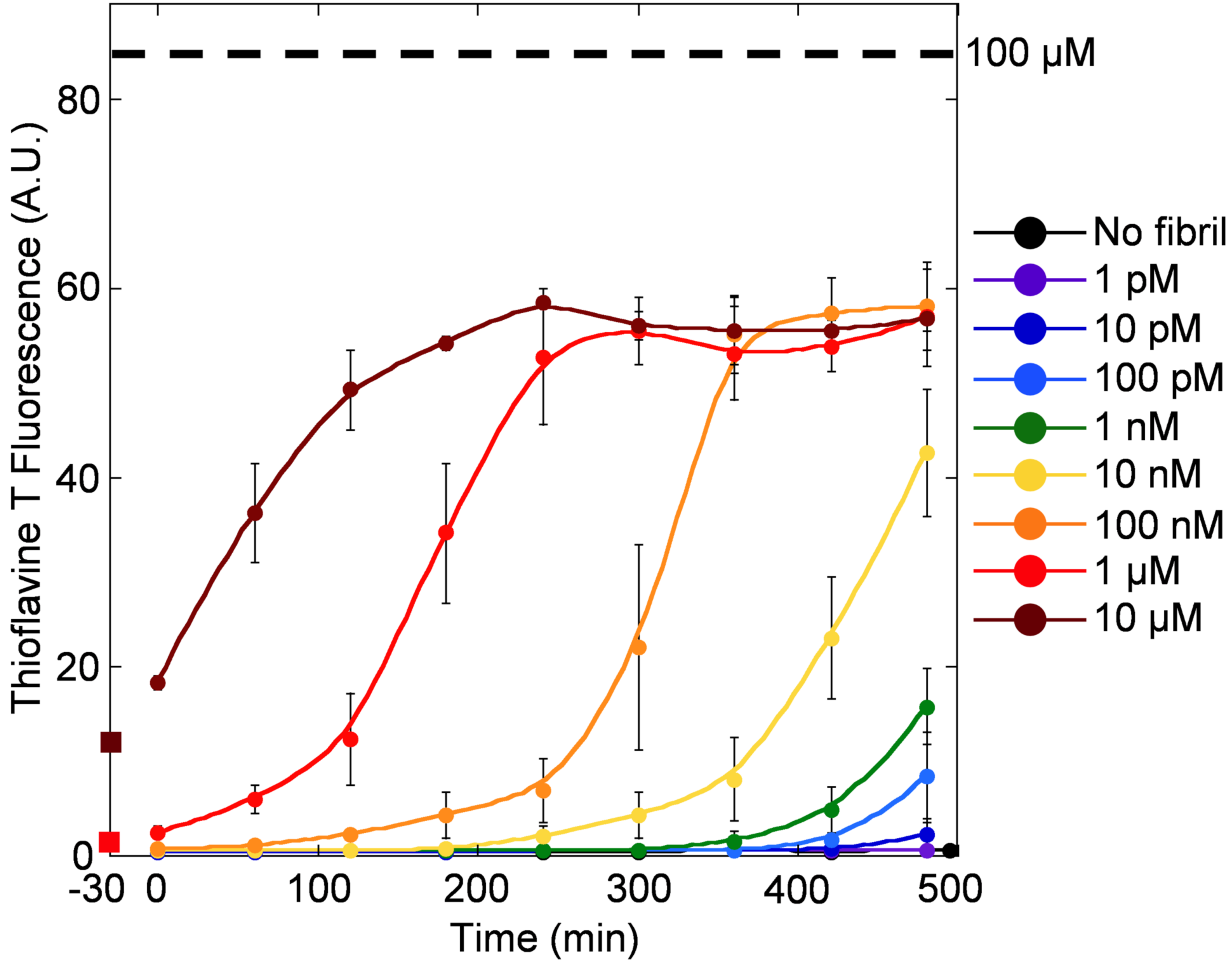
348 Supplementary FIGURE 1. **PMCA kinetics raw data.** PMCA amplification of gastrointestinal
349 biopsies homogenates from controls (rectum and sigmoid colon) or PD patients (rectum and
350 sigmoid colon and antrum) followed by ThT fluorescence measurement. PMCA reactions
351 were performed in duplicate. Individual replicates and mean values are drawn for the 29
352 subjects in separated graphs.

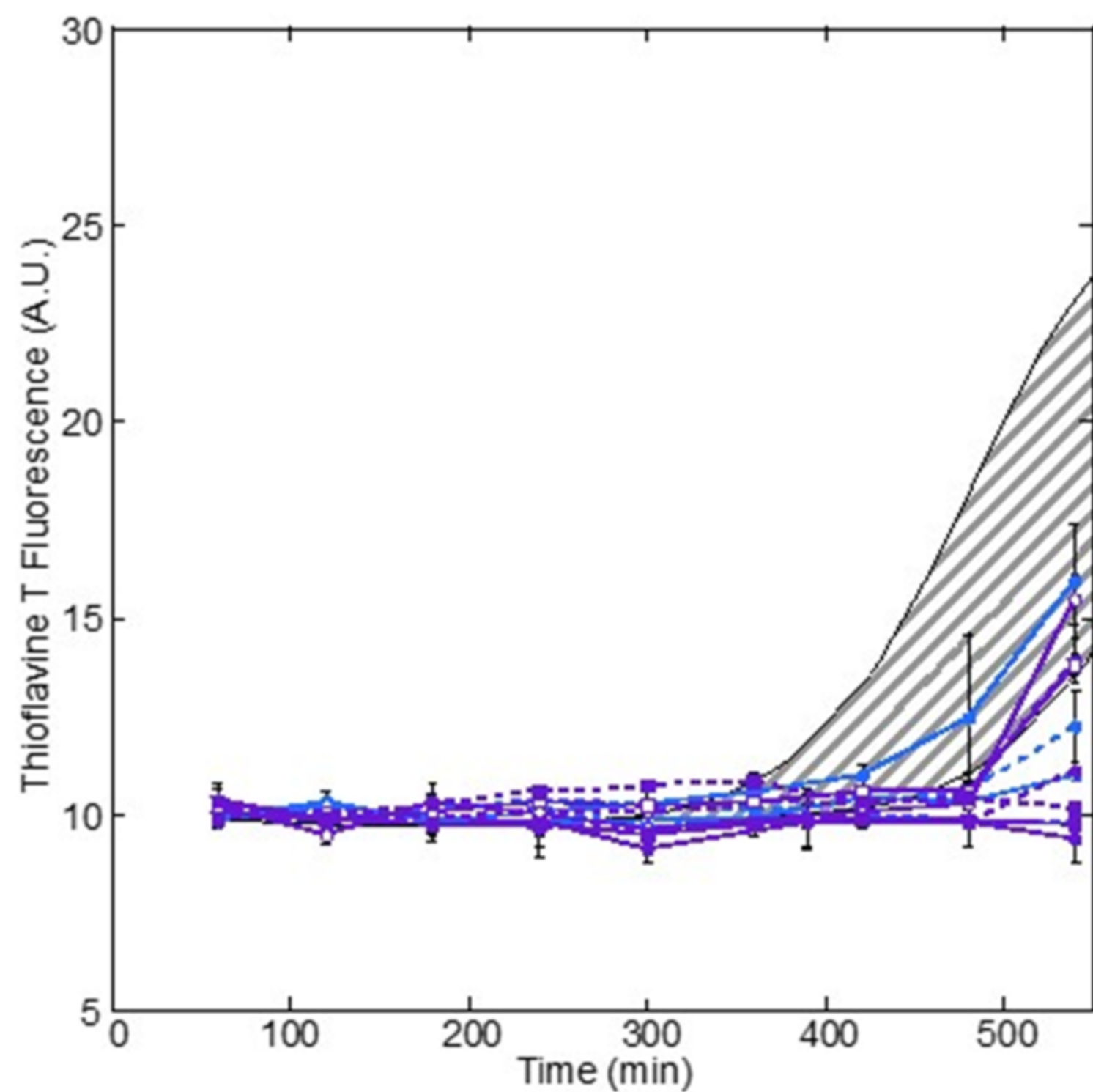
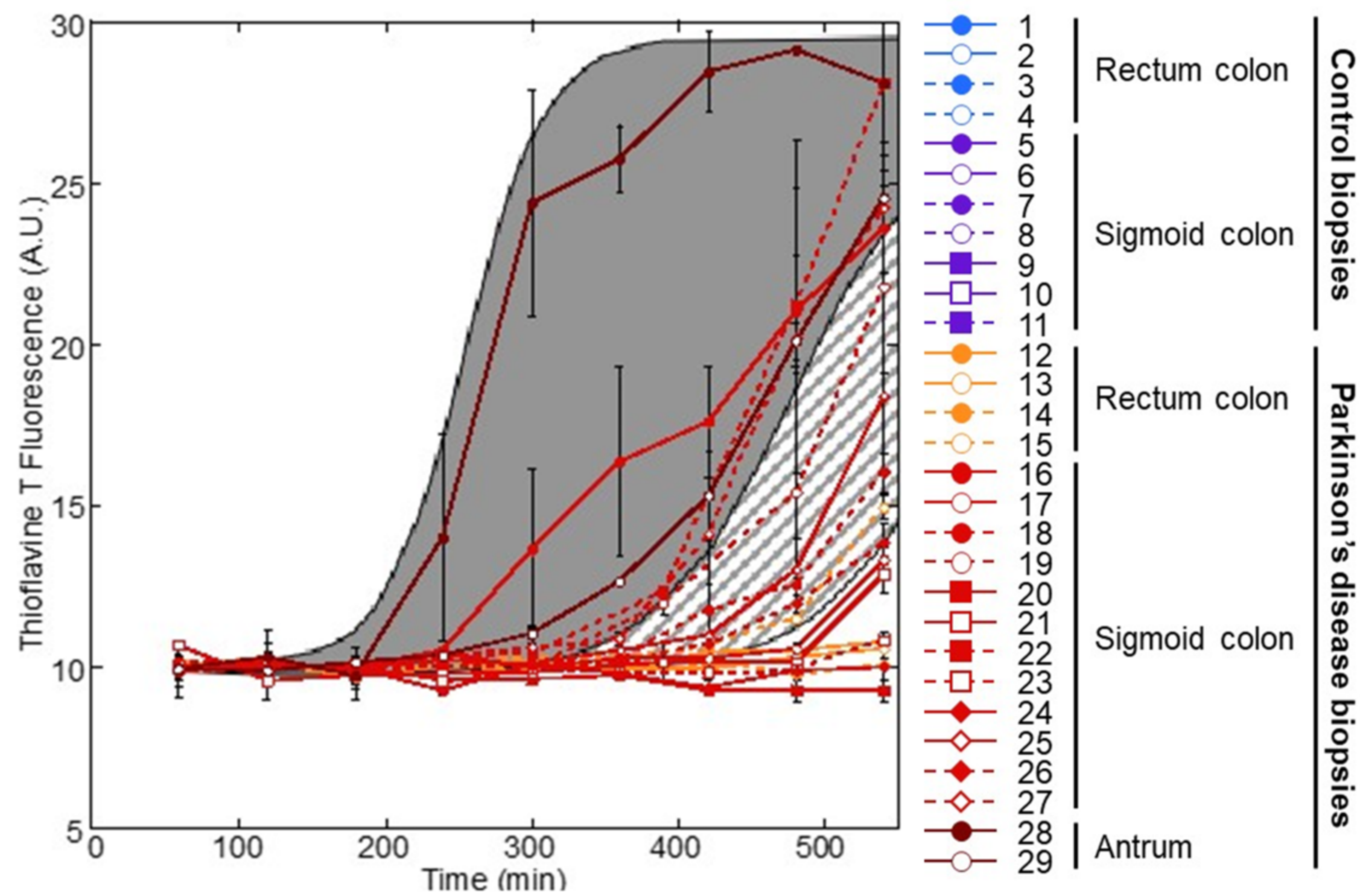
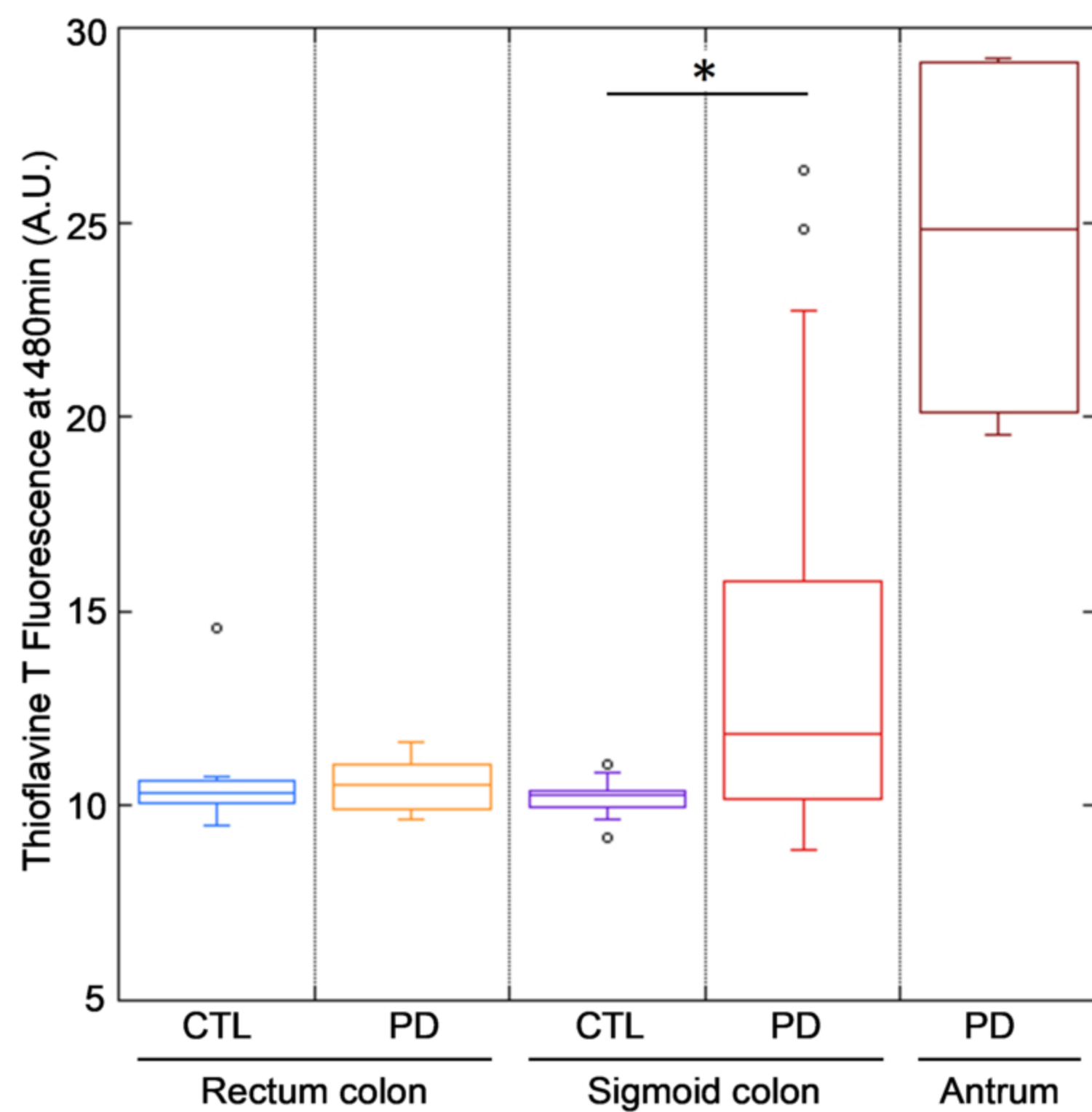
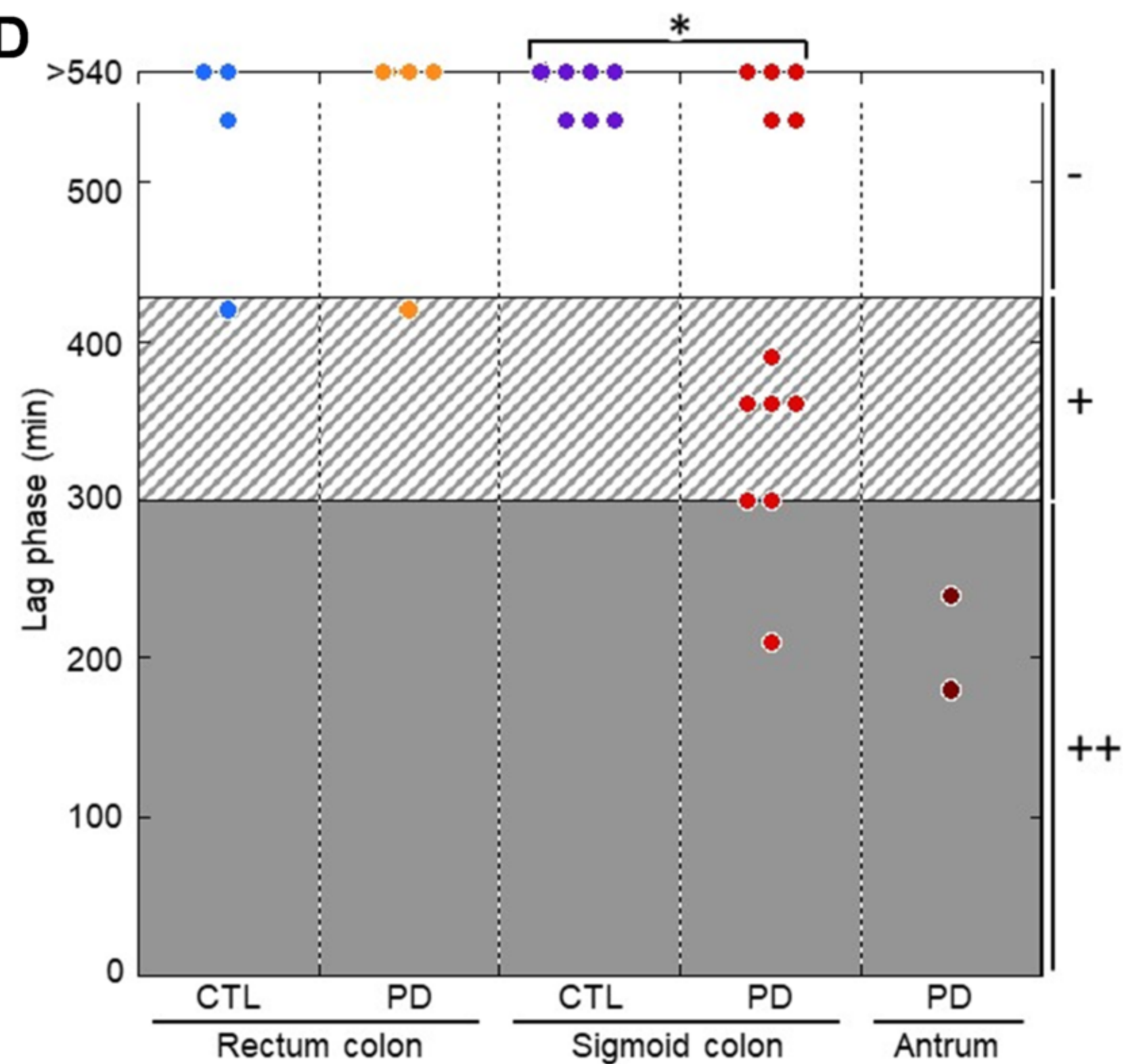
	Age, sex	Diagnosis	Biopsy			PMCA results				
			Site	Number	PASH	Amplification	Lag time	ThT increase at 480min for each duplicate		
1	68/M	Control	Rectum	4	(0/1)	+	420	4,4	<1	
2	58/F			4	(0/1)	-	>540	<1	<1	
3	38/F			4	NA	-	540	<1	<1	
4	43/M			4	NA	-	>540	<1	<1	
5	62/M		Sigmoid	3	NA	-	>540	<1	<1	
6	66/M			3	NA	-	540	<1	<1	
7	61/F			3	NA	-	>540	<1	<1	
8	72/M			4	NA	-	540	<1	<1	
9	56/F			4	NA	-	>540	<1	<1	
10	53/M			4	(0/2)	-	540	<1	<1	
11	33/M			4	NA	-	>540	<1	<1	
12	67/M	Parkinson's disease	Rectum	4	(0/1)	-	>540	<1	<1	
13	66/M			4	(0/1)	-	>540	<1	<1	
14	55/M			4	(0/1)	-	>540	<1	<1	
15	68/F			4	(0/1)	+	420	1,4	1,2	
16	70/M		Sigmoid	4	(1/2)	++	210	12,6	9,1	
17	70/M			4	(0/2)	-	540	<1	<1	
18	55/M			4	NA	+	360	2,6	2,0	
19	47/F			3	NA	+	300	8,9	1,5	
20	53/M			2	(0/2)	-	>540	<1	<1	
21	67/M			3	(0/2)	-	540	<1	<1	
22	58/M			3	(2/2)	++	300	16,1	5,8	
23	69/M			2	(2/2)	-	>540	<1	<1	
24	72/F			2	(0/2)	-	>540	<1	<1	
25	59/M			2	(0/2)	+	390	3,8	1,8	
26	58/F			2	(2/2)	+	360	2,1	1,5	
27	70/M			2	(2/2)	++	360	14,6	5,4	
28	72/F			Antrum	4	NA	++	180	19,0	18,8
29	70/F				4	NA	++	240	10,5	9,3

354 **Table 1 : Histology and amplification summary.**

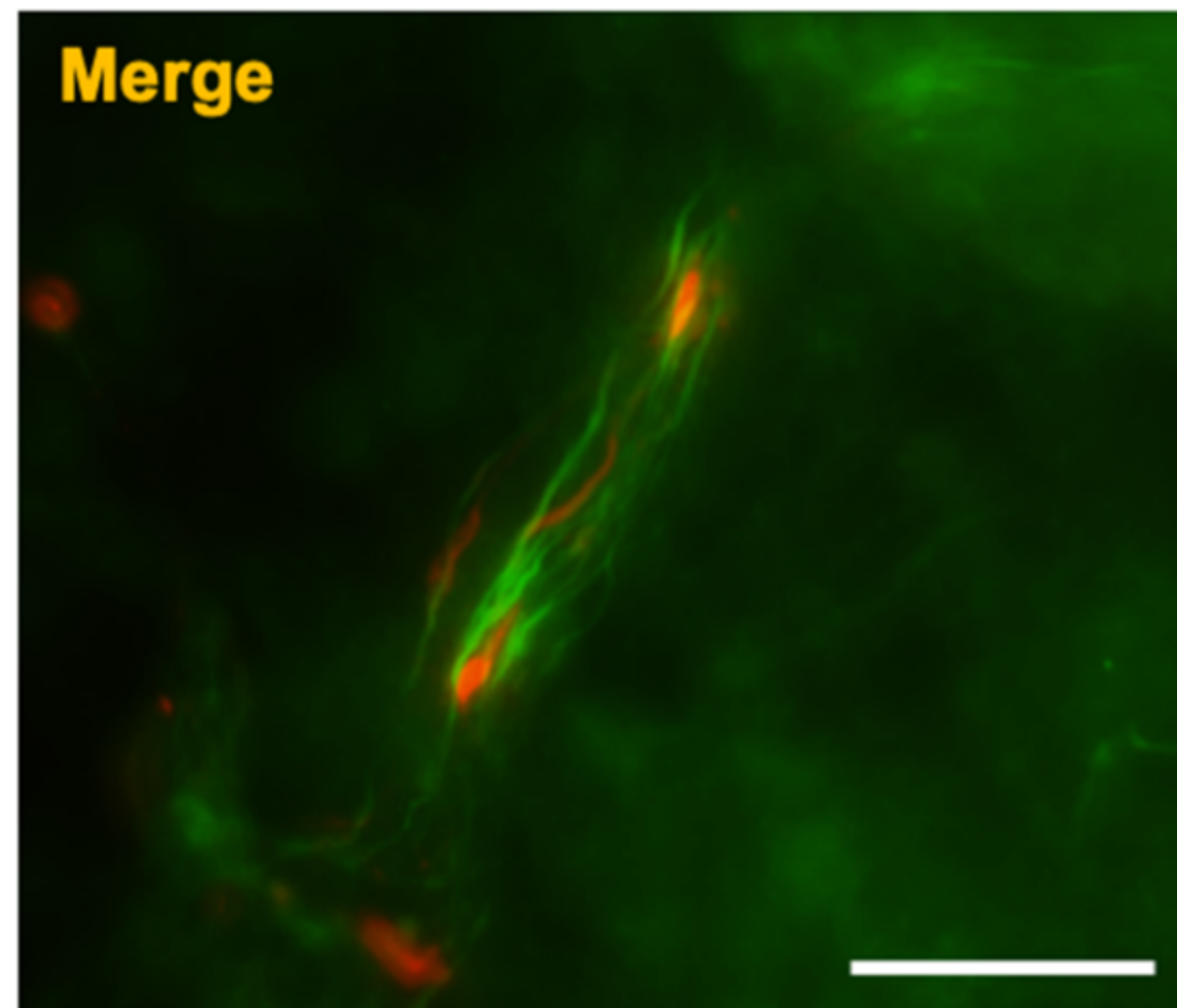
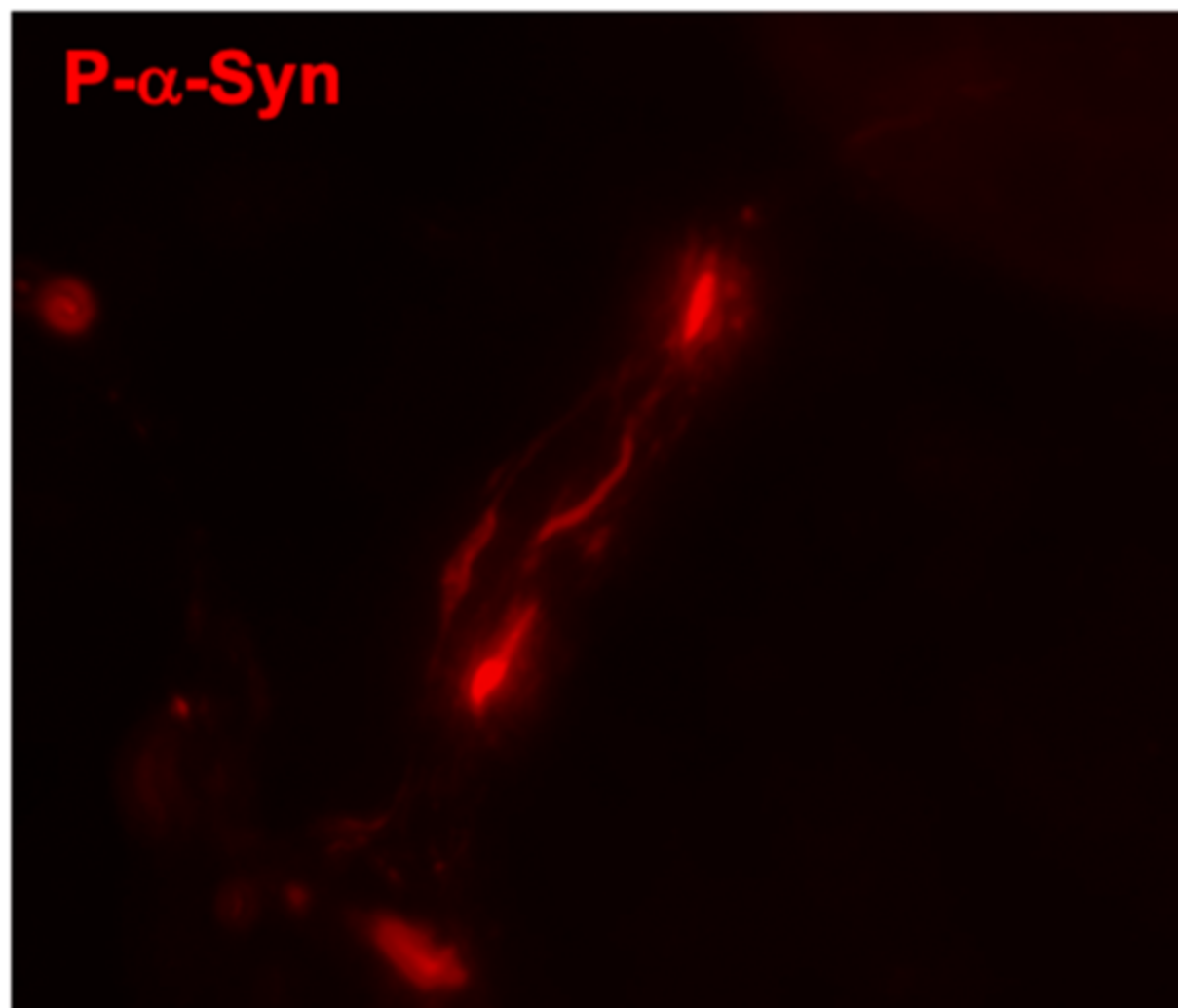
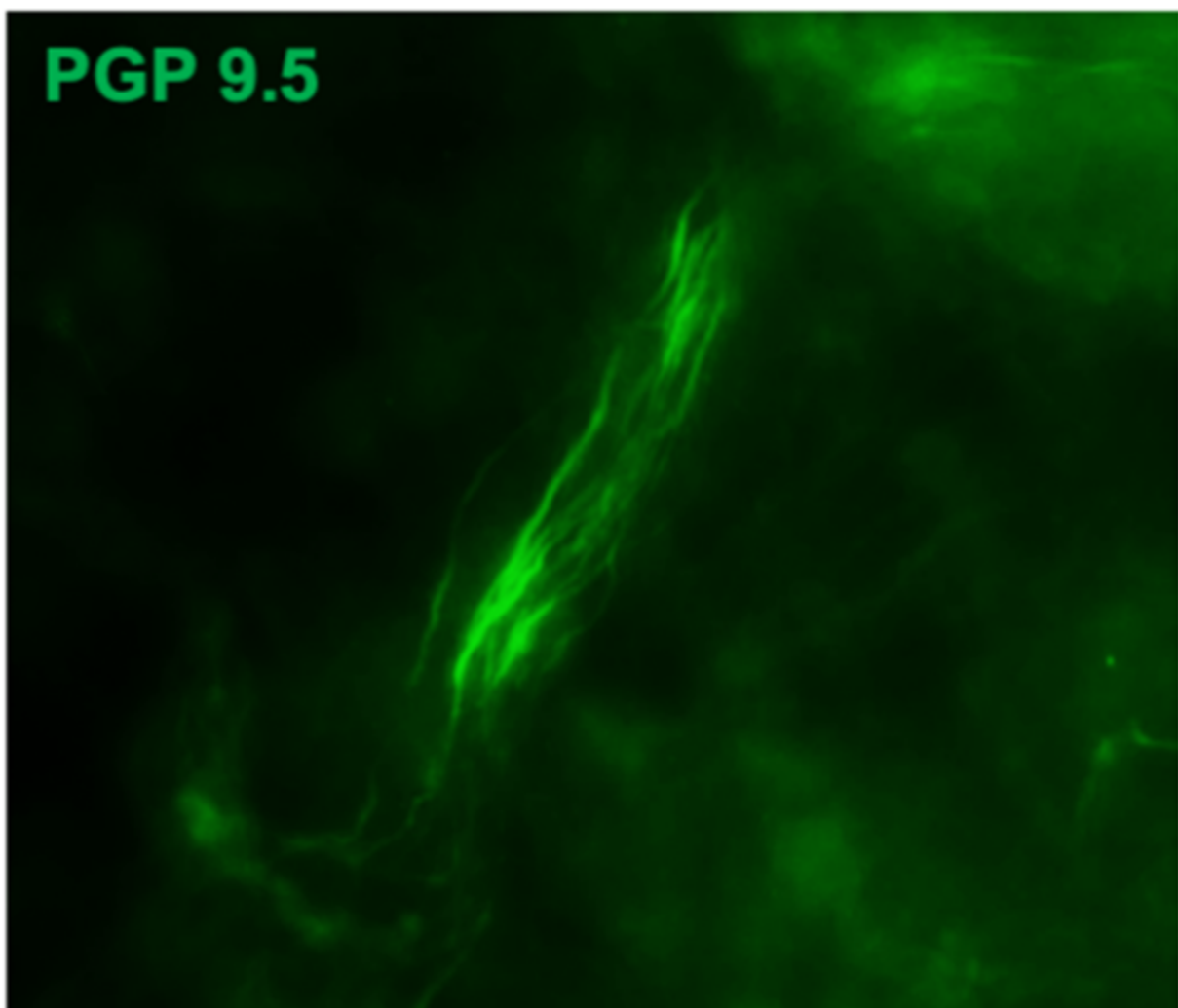
355 Age and sex: age of patients at the time of the biopsies and gender; Diagnosis: differentiates
356 controls from parkinsonian patients; Biopsy: site of the biopsy (Site), number of biopsies
357 used in the PMCA assay (Number), result of the histological analysis (PASH; NA = not
358 assessed; (X/Y) = number of positive biopsy[ies]); PMCA results: amplification efficacy ranked
359 base on lag phase duration and ThT increase (Amplification; ++ : high amplification; + : low
360 amplification; - : no amplification detected), lag phase duration in minutes (Lag Time), ThT

361 increase calculated between time point 60 minutes and 480 minutes (ThT increase at
362 480min for each duplicate).



A**B****C****D**

PD



CTL

