



HAL
open science

Optimization of sample preparation for MRI of formaldehyde-fixed brains

Yann Leprince, Benoît Schmitt, Elodie Chaillou, Christophe Destrieux, Laurent Barantin, Alexandre Vignaud, Denis Rivière, Cyril Poupon

► **To cite this version:**

Yann Leprince, Benoît Schmitt, Elodie Chaillou, Christophe Destrieux, Laurent Barantin, et al.. Optimization of sample preparation for MRI of formaldehyde-fixed brains. 23rd Annual Meeting of ISMRM, May 2015, Toronto, Canada. pp.2283. cea-01184929

HAL Id: cea-01184929

<https://cea.hal.science/cea-01184929>

Submitted on 18 Aug 2015

HAL is a multi-disciplinary open access archive for the deposit and dissemination of scientific research documents, whether they are published or not. The documents may come from teaching and research institutions in France or abroad, or from public or private research centers.

L'archive ouverte pluridisciplinaire **HAL**, est destinée au dépôt et à la diffusion de documents scientifiques de niveau recherche, publiés ou non, émanant des établissements d'enseignement et de recherche français ou étrangers, des laboratoires publics ou privés.



Distributed under a Creative Commons Attribution - ShareAlike 4.0 International License

Context: MRI of post-mortem samples

Post-mortem MR imaging is useful for several applications:

- acquiring high quality anatomical reference images thanks to long scanning time;
- comparing MR images with gold standard histological imaging;
- studying autopsy samples;
- testing sequences on an anatomically realistic phantom.

However, post-mortem tissue needs to be fixed in order to prevent its degradation. **Fixation modifies the properties of the tissue (relaxivity, diffusion)** by inducing chemical changes [Tovi and Ericsson, 1992].

Purpose and objective

The change of tissue properties affects MR imaging: in particular, **T_2 is decreased by fixation, which is detrimental to SNR.**

Understanding the kinetics of the fixation and associated tissue changes is required to improve the preparation of tissue samples for MR imaging. Therefore, **this study measures the evolution of several parameters relevant to MR imaging during post-fixation in formaldehyde over a period of months.**

Moreover, it has been shown that soaking a fixed tissue sample in saline solution prior to imaging can partially restore the T_2 of the tissue and is beneficial to the SNR of acquired MR data. [D'Arceuil et al, 2007] [Shepherd et al, 2009]

Therefore, this study also measures the evolution of the same parameters during subsequent soaking in saline solution.

Overall design of the study

Two healthy ewes (adult two-year-old female sheep, *ovis aries*) were used, in accordance with local animal regulation (authorization A37801 of the French Ministry of Agriculture).

The following procedure was used for each animal:

- euthanasia using massive injection of barbiturate;
- immediate perfusion of the head with 4 L PFA at 4°C to prevent early tissue degradation;
- brain extraction;
- immersion of the brain in PFA.

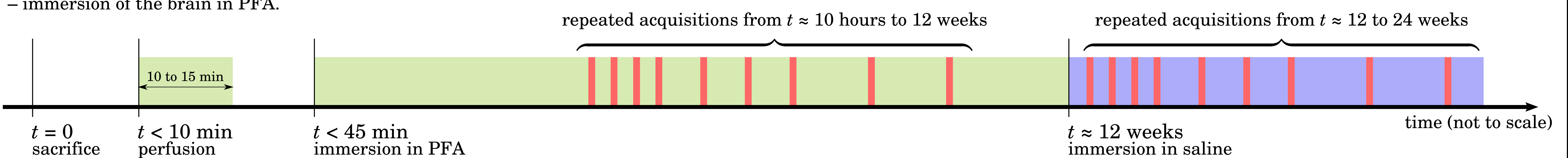
The fixative solution, which is called **PFA** for short, is composed of 4 % formaldehyde prepared by dissolving paraformaldehyde powder in phosphate-buffered saline (PBS).

Both brains were imaged repeatedly on a clinical 7 T MRI system over a period of 3 months during immersion in PFA. After that, one brain was immersed in isotonic saline solution for washing, and imaged repeatedly for 3 months.

Initially two acquisitions per day were performed, then the frequency was decreased.

For the duration of each acquisition session the brains were transferred in Fluorinert™, a fluorocarbon-based fluid that creates no signal and has a similar susceptibility to cerebrospinal fluid.

Maps of T_1 , T_2 , T_2^* , and diffusion were acquired during each session. Average values over white matter and grey matter were extracted in hand-delimited regions of interest (see details below).



Imaging and analysis methods

High-resolution anatomical image

During each session, an anatomical image was acquired for registration using a 3D turbo spin echo sequence with variable flip angle, at 0.8 mm isotropic resolution (SPACE, TR = 4000 ms, TE = 275 ms, GRAPPA 3, turbo factor 164, echo train length 654 ms, bandwidth 334 Hz/Px, acquisition time 2 min 33 s). In addition, one session was dedicated to acquiring an image at 0.3 mm isotropic resolution for anatomical reference, using a 3D turbo spin echo sequence with variable flip angle (SPACE, TR = 4000 ms, TE = 273 ms, turbo factor 144, echo train length 851 ms, bandwidth 181 Hz/Px, acquisition time 1 h 24 min).

Quantitative T_1 mapping

The longitudinal relaxation time T_1 was mapped using variable flip angle–actual flip angle imaging (VAFI) [Hurley et al. 2012]. The variable flip angle acquisition used a partially-spoiled steady-state free precession sequence (pSSFP) with 1 mm isotropic resolution, TE = 3 ms, TR = 14 ms, FA₁ = 5°, FA₂ = 20°, GRAPPA 3, bandwidth 250 Hz/Px. The actual flip angle acquisition [Amadon et al, 2008] used 4 mm isotropic resolution, TE = 3 ms, TR = 130 ms, n = 5, FA = 60°, GRAPPA 3, bandwidth 1560 Hz/Px. Total acquisition time was 12 min 7 s. Maps of T_1 were reconstructed using an in-house implementation of the VAFI method.

Quantitative T_2 mapping

The transverse relaxation time T_2 was mapped using spin echo echo-planar imaging (EPI) with 1.7 mm isotropic resolution, 36 linearly spaced TE values between 15 ms and 80 ms, TR = 17 s, GRAPPA 3, bandwidth 1680 Hz/Px, acquisition time 11 min 45 s. The signal decay across echos was fitted with a least-squares regression of a single exponential decay using a Levenberg-Marquardt algorithm implemented in PTK, an in-house software suite.

Quantitative T_2^* mapping

The effective transverse relaxation time T_2^* was mapped using a multi-echo gradient echo sequence with 1 mm isotropic resolution, with 12 linearly spaced TE values between 1.6 ms and 21.5 ms, TR = 30 ms, GRAPPA 3, bandwidth 1950 Hz/Px, acquisition time 6 min 40 s. The signal decay across echos was fitted with a least-squares regression of a single exponential decay using a Levenberg-Marquardt algorithm implemented in PTK, an in-house software suite.

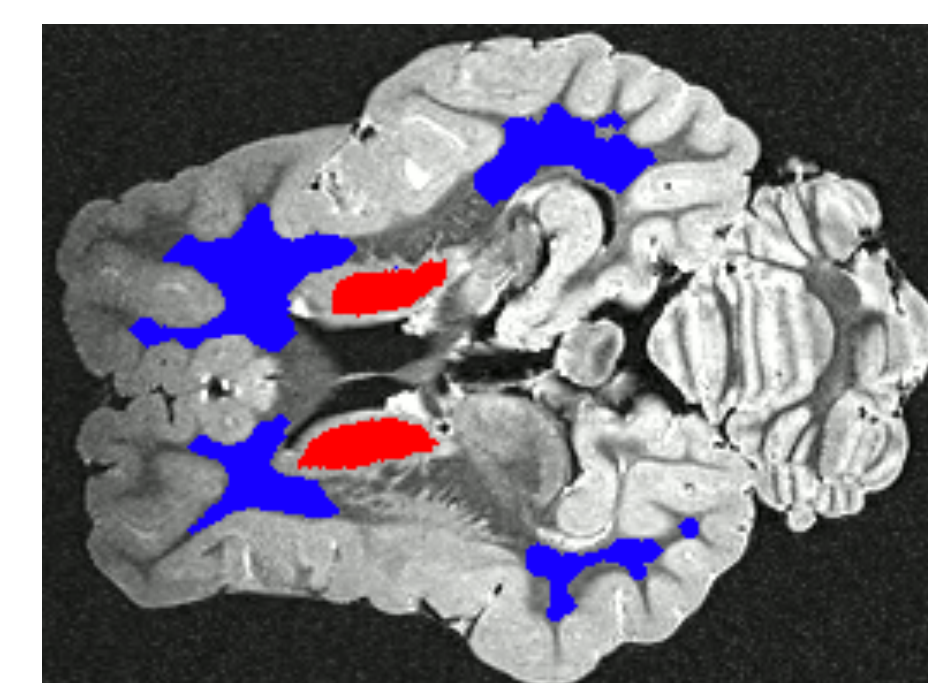
Diffusion imaging

Diffusion-weighted images were acquired using spin echo EPI with 2 mm isotropic resolution, 256 diffusion directions, b = 4500 s/mm², TE = 82 ms, TR = 9000 ms, GRAPPA 3, bandwidth 1954 Hz/Px, acquisition time 39 min 18 s. The apparent diffusion coefficient (ADC) and fractional anisotropy (FA) were extracted using a first-order tensor model, using the DiPy software.



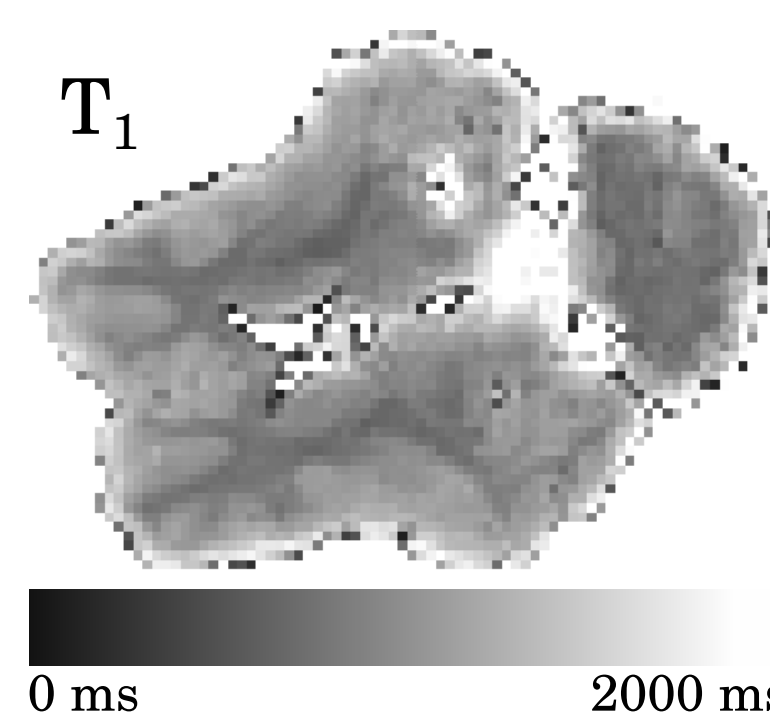
ROI (region of interest) analysis

The parametric maps were analyzed using regions of interest (ROIs) manually defined on the high-resolution anatomical images, representing the white matter and caudate nuclei, respectively. The ROIs were transformed into the referential of each parametric map. The intra-session transformation from the parametric map to the anatomical image was extracted from the DICOM headers. The inter-session transformation was estimated by rigid registration of the anatomical image onto the high-resolution anatomical image using FLIRT version 6.0 [Jenkinson et al, 2001, 2002] with a correlation ratio cost function. Voxels that contained partial volumes at the boundary of ROIs were excluded from the analysis.

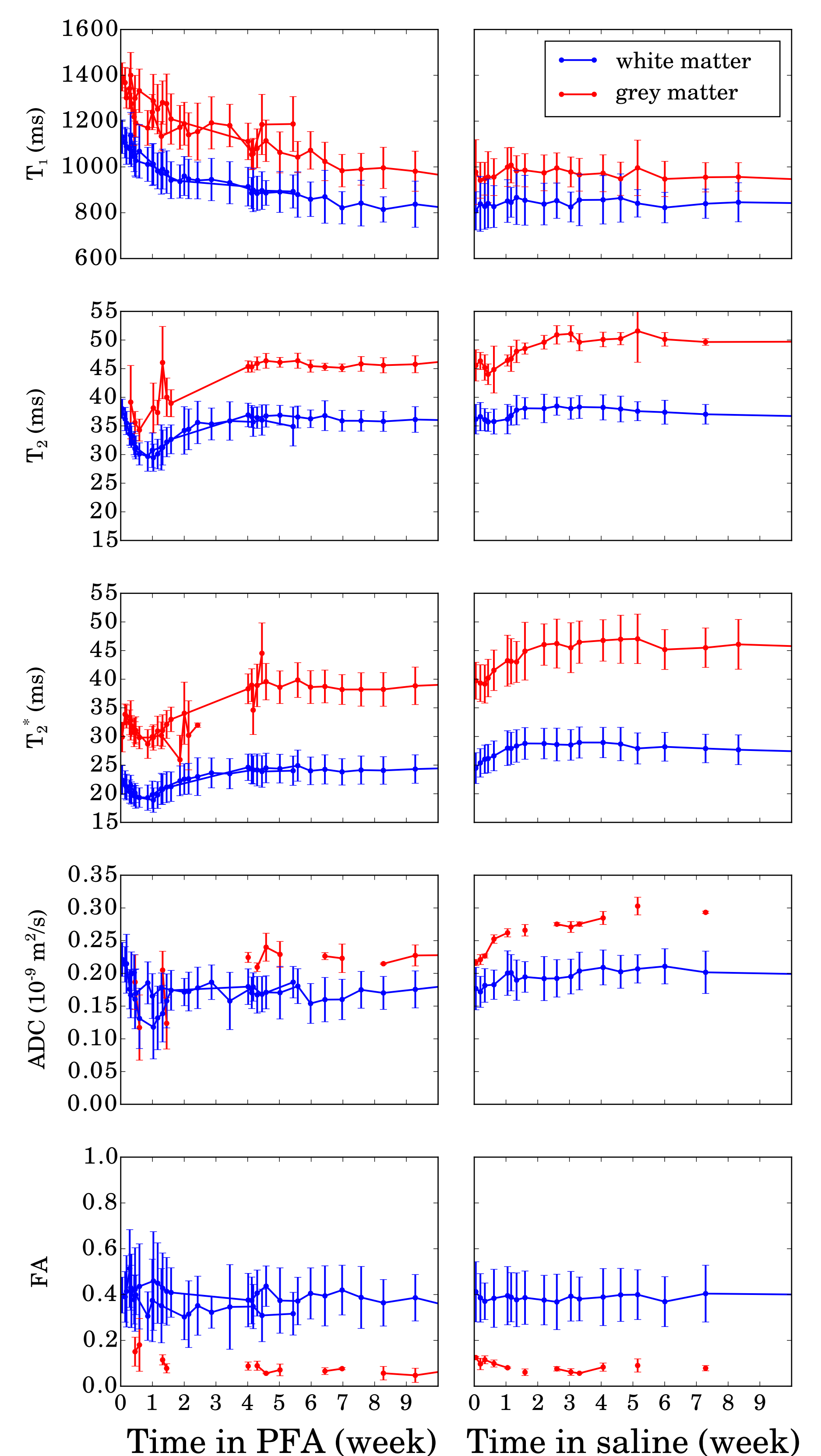
Results



Axial view of the 3D ROIs, superimposed on the 0.3 mm anatomical reference scan



Example axial view of relaxometry maps, 4 weeks into PFA



Each brain is represented by a different curve. Error bars represent average \pm standard deviation in the ROI. Note: the caudate nuclei averages are noisy with a few outliers and missing points, because they contain very few voxels for lower resolution maps.

Discussion and conclusion

- ✓ Soaking the tissue in saline had the intended effect of restoring higher T_2 , T_2^* , and diffusivity values.
- ✓ The slow decrease of T_1 during fixation is consistent with previously published data [Tovi and Ericsson, 1992], as well as the decrease of diffusivity and stability of anisotropy [D'Arceuil et al, 2007].
- ✓ Good reproducibility is observed where data is available for both brains.
- ? The rebound of T_2 and T_2^* after one week was not expected. A similar phenomenon was previously observed, and attributed to early decomposition of unfixed deep tissue [Dawe et al, 2009]. However, the present study uses fixation by perfusion, which is intended to stop such degradation by exposing all the tissue to fixative early after death. Instead, we hypothesize that this rebound is due to the degradation of the PFA solution itself through precipitation of monomeric formaldehyde into paraformaldehyde, effectively lowering the formaldehyde concentration as the solution degrades. This could be avoided:
 - either by regularly changing the fixative;
 - or by using formalin, which includes methanol to prevent polymerization of the formaldehyde.
- ➔ We can derive recommendations for optimal soaking times:
 - fixation in PFA is stable after \approx 8 weeks;
 - soaking in saline solution achieves maximum recovery after \approx 3 weeks;
 - these values are expected to be longer for larger specimens such as human brains, which require longer penetration time.

References

- Amadon, A. & Boulant, N. MAFI sequence: simultaneous cartography of B0 and B1. ISMRM 2008, Toronto, Canada, 1248.
 D'Arceuil, H. E., Westmoreland, S. & de Crespiigny, A. J. An approach to high resolution diffusion tensor imaging in fixed primate brain. *NeuroImage* 35, 553–565 (2007).
 Dawe, R. J., Bennett, D. A., Schneider, J. A., Vasireddi, S. K. & Arfanakis, K. Postmortem MRI of human brain hemispheres: T2 relaxation times during formaldehyde fixation. *MRM* 61, 810–818 (2009).
 Jenkinson, M., Bannister, P., Brady, M. & Smith, S. Improved Optimization for the Robust and Accurate Linear Registration and Motion Correction of Brain Images. *NeuroImage* 17, 825–841 (2002).
 Jenkinson, M. & Smith, S. A global optimisation method for robust affine registration of brain images. *Medical Image Analysis* 5, 143–156 (2001).
 Hurley, S. A. et al. Simultaneous variable flip angle–actual flip angle imaging method for improved accuracy and precision of three-dimensional T1 and B1 measurements. *MRM* 68, 54–64 (2012).
 Shepherd, T. M., Thelwall, P. E., Stanisz, G. J. & Blackband, S. J. Aldehyde fixative solutions alter the water relaxation and diffusion properties of nervous tissue. *MRM* 62, 26–34 (2009).
 Tovi, M. & Ericsson, A. Measurements of T1 and T2 over Time in Formalin-Fixed Human Whole-Brain Specimens. *Acta Radiologica* 33, 400–404 (1992).