



Expression of HLA-G in inflammatory bowel disease provides a potential way to distinguish between ulcerative colitis and Crohn's disease.

M. I. Torres, Magali Le Discorde, P. Lorite, A. Ríos, M. A. Gassull, A. Gil, J. Maldonado, J. Dausset, E. D. Carosella

► To cite this version:

M. I. Torres, Magali Le Discorde, P. Lorite, A. Ríos, M. A. Gassull, et al.. Expression of HLA-G in inflammatory bowel disease provides a potential way to distinguish between ulcerative colitis and Crohn's disease.. International Immunology, 2004, 16 (4), pp.579-83. 10.1093/intimm/dxh061 . cea-00268923

HAL Id: cea-00268923

<https://cea.hal.science/cea-00268923>

Submitted on 1 Apr 2008

HAL is a multi-disciplinary open access archive for the deposit and dissemination of scientific research documents, whether they are published or not. The documents may come from teaching and research institutions in France or abroad, or from public or private research centers.

L'archive ouverte pluridisciplinaire **HAL**, est destinée au dépôt et à la diffusion de documents scientifiques de niveau recherche, publiés ou non, émanant des établissements d'enseignement et de recherche français ou étrangers, des laboratoires publics ou privés.

Expression of HLA-G in inflammatory bowel disease provides a potential way to distinguish between ulcerative colitis and Crohn's disease

M. I. Torres¹, M. Le Discorde², P. Lorite¹, A. Ríos³, M. A. Gassull⁴, A. Gil⁵, J. Maldonado⁶, J. Dausset² and E. D. Carosella²

¹Department of Experimental Biology, University of Jaén, Jaén, Spain

²Service de Recherches en Hemato-Immunologie, Commissariat a l'Energie Atomique, Department de Recherche Medicale, Hopital Saint-Louis, Paris, France

³Department of Cell Biology, University of Granada, Granada, Spain

⁴Department of Gastroenterology, Hospital Universitari Germans Trias i Pujol, Badalona, Catalonia, Spain

⁵Department of Biochemistry and Molecular Biology, University of Granada, Granada, Spain

⁶Department of Paediatrics, Facultad de Medicina, University of Granada, Granada, Spain

Keywords: Crohn's disease, HLA-G, inflammatory bowel disease, ulcerative colitis

Abstract

In addition to being involved in nutrient uptake, the epithelial mucosa constitute the first line of defense against microbial pathogens. A direct consequence of this physiological function is a very complex network of immunological interactions that lead to a strong control of the mucosal immune balance. The dysfunction of immunological tolerance is likely to be a cause of inflammatory bowel disease (IBD), ulcerative colitis (UC) and Crohn's disease (CD). HLA-G is a non-classical major histocompatibility complex (HLA) class I molecule, which is highly expressed by human cytotrophoblast cells. These cells play a role in immune tolerance by protecting trophoblasts from being killed by uterine NK cells. Because of the deregulation of immune system activity in IBD, as well as the immunoregulatory role of HLA-G, we have analyzed the expression of HLA-G in intestinal biopsies of patients with UC and CD. Our study shows that the differential expression of HLA-G provides a potential way to distinguish between UC and CD. Although the reason for this differential expression is unclear, it might involve a different mechanism of immune regulation. In addition, we demonstrate that in the lamina propria of the colon of patients with UC, IL-10 is strongly expressed. In conclusion, the presence of HLA-G on the surface of intestinal epithelial cell in patients with UC lends support to the notion that this molecule may serve as a regulator of mucosal immune responses to antigens of undefined origin. Thus, this different pattern of HLA-G expression may help to differentiate between the immunopathogenesis of CD and UC.

Introduction

Ulcerative Colitis (UC) and Crohn's disease (CD), the two main forms of inflammatory bowel disease (IBD), are chronic and spontaneously relapsing disorders, whose frequency is increasing. Both disorders appear to be immunologically mediated. There is compelling evidence that the deregulation of the mucosal immune system is a major contributing factor to the pathogenesis of IBD (1,2). Although their etiology is unclear, the pathogenesis of these diseases represents the

outcome of three essential, interactive cofactors: (i) the host susceptibility, (ii) the enteric microflora and (iii) the mucosal immunity (3). The mucosal immune system senses the local microenvironment, being able to recognize and avoid reactions to commensal flora, whilst retaining its capacity to respond to episodic challenge from pathogens (4).

Histologically, whereas UC is characterized by continuous mucosal inflammation with crypt abscesses and ulcers that

typically spread from the most caudal part of the rectum, CD is associated with segmental and transmural inflammation, fistulas, edema and granulomas. The nature of the immune response and the cytokine profile are under genetic control, and it determines the features of the inflammatory process in IBD. Thus, CD is associated with the production and secretion of type 1 helper T cell (Th) cytokines, such as IFN- γ , tumor necrosis factor- α and IL-12 (1,5). In UC, the pattern of cytokine is less clear, with a modified Th2 response associated with IL-15 and IL-10 (1–6). Among the cytokines implicated in UC, IL-10 plays a key role in the regulation of the mucosal inflammation, promoting physiological activation, and preventing the pathological inflammation characteristic of IBD (7).

HLA-G is a non-classical major histocompatibility complex (HLA) class I molecule, which is highly expressed by human cytotrophoblast cells that constitute the maternal–fetal interface (8–10) and protect trophoblasts from being killed by uterine NK cells. Therefore, cytotrophoblast cells are implicated in immune tolerance (11). The distribution of HLA-G is tissue-restricted, and shows limited polymorphism and alternative transcription of spliced mRNAs that encode seven different isoforms: four membrane-bound (G1–G4) and three soluble proteins (G5–G7) (12,13). These HLA-G isoforms inhibit NK cytotoxicity from polyclonal peripheral blood mononuclear cells and cytotoxic T cell function during the primary allogeneic reaction (14). Several studies have also shown that HLA-G expression allows tumor cells to escape from normal immune responses and to proliferate (15,16). Recently, soluble HLA-G found in biopsies and serum from patients undergoing heart transplantation has been associated with a better graft acceptance (17).

In view of currently available information on UC and CD, characterized by alterations in the balance of pro-inflammatory and regulatory cytokines, and a deregulation of the immune response, and considering the immunoregulatory role of HLA-G, we analyze the expression of HLA-G in intestinal biopsies of patients with CD and UC. In addition, we investigated the expression of IL-10 in gut tissues from these patients.

Method

Patients

Forty-three patients entered the study, including 24 patients with UC and 19 patients with CD (the patients were followed at the German Trias i Pujol Hospital of Badalona, Barcelona, Spain and the Clinic Hospital of Granada, Spain). The diagnosis of UC and CD was based on standard clinical, radiological endoscopic and histologic criteria. The pathologists graded the biopsies.

Immunohistochemistry

Samples fixed in formalin and paraffin-embedded were used for immunohistochemistry. HLA-G and IL-10 were detected using a monoclonal antibody 4H84 [kindly provided by S. Fisher and M. McMaster (9)] that recognized all denatured HLA-G isoforms, and an anti-human IL-10 antibody (Santa Cruz Biotechnology, Inc., Santa Cruz, CA), respectively. An IgG2a isotypic mAb (Sigma) was used as negative control.

Immunohistochemical staining was performed using the UltraTech HRP Streptavidin–Biotin Universal detection system (Immunotech, France). After deparaffinization and rehydration, sections were microwaved in 10 mM citrate buffer (pH 6.0) for antigen retrieval. Sections were cooled in PBS, and the endogenous peroxidase activity was quenched with 3% hydrogen peroxide in distilled water. Sections were then treated with the protein blocking agent, incubated sequentially with the primary antibody, after with a biotinylated secondary antibody, and with the streptavidin–peroxidase reagent. The immunoreaction was visualized with chromogen working solution AEC (Immunotech, France). Finally, the sections were counterstained with hematoxylin. A positive control and a negative control tissue were always considered. The immunoreactive score was determined by the sum of extension and intensity in the samples. The intensity of staining was measured in two sections by two independent observers, and scored as 0 for negative, 1 for weakly positive, 2 for moderately positive and 3 for strongly positive. The extent of positive immunoreactivity was estimated as 0 for negative, 1 for positive immunoreactivity for 25% of the cells, 2 for 50%, 3 for 75% and 4 for 100%. A section was considered positive when over 30% of cells were stained.

Results

Samples of colon from 43 patients were examined and the histological diagnosis for active diseases was based on the degree of infiltration of neutrophils in the intestinal lamina propria, crypts and epithelium. The expression of HLA-G antigens in these samples was analyzed. Our results provide the first evidence of HLA-G expression in UC patients (Fig. 1A, C and E). Indeed, all patients with UC ($n = 24$) tested showed a positive expression of HLA-G, as demonstrated by immunohistochemistry using monoclonal antibody 4H84, which recognizes all denatured HLA-G isoforms. In contrast, HLA-G expression was totally absent in CD patients (Fig. 1B). Therefore, this study indicates the unexpected expression of the HLA-G proteins in UC, but never in CD.

An isotype-matched negative staining control is shown in Fig. 1(D). In addition, there was no evidence of HLA-G expression in intestinal biopsies of control patients ($n = 3$) (data not shown). HLA-G was highly expressed in all intestinal tissues of UC, regardless of the intestinal location (ascending, transverse, descending colon, or ileum), and of the medical history and regimen of the patients. The expression of HLA-G was restricted to the apical surface of intestinal epithelial cells (IECs) in the epithelial layer in the intestinal mucosa (Fig. 1A) and Lieberkun crypts (Fig. 1E). At higher magnification, this intense apical staining can be observed (close-up view, Fig. 1A). IECs from sections both actively inflamed and uninvolved areas of UC revealed similar patterns of staining. No immunoreactivity was found in the other mucosal cell types such as lymphocytes, macrophages, endothelial cells and Peyer's patches, as shown in Fig. 1(E). The IECs have extensive contact with T lymphocytes both within the epithelium and in the underlying lamina propria. IECs are capable of expressing HLA-G molecule in mucosal inflammation produced by ulcerative colitis with the associated production of inflammatory cytokines.

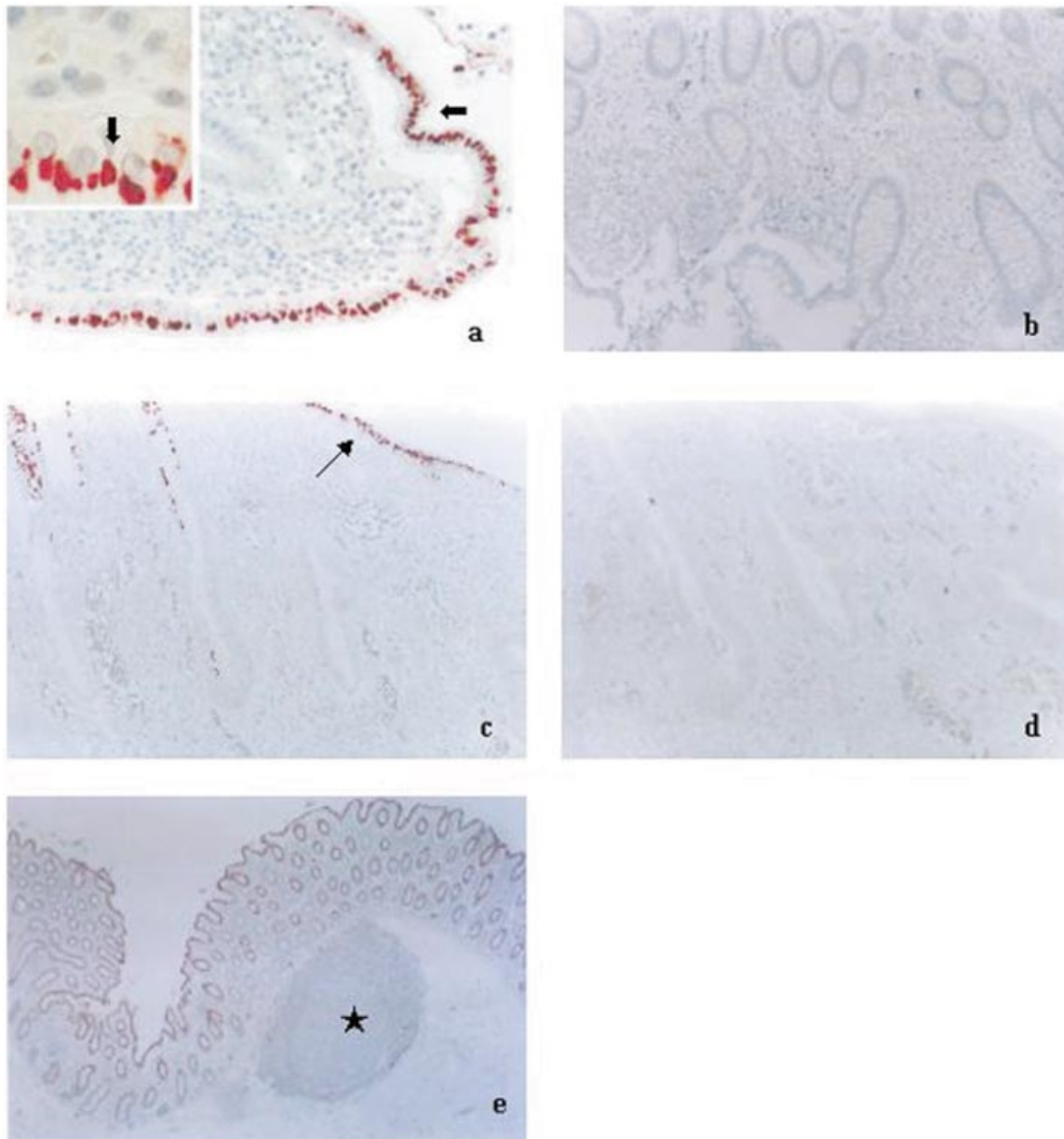


Fig. 1. (a) Immunohistochemistry of HLA-G expression in patients with UC. We observed a strong reactivity in the apical surface of IECs in the epithelial layer in the intestinal mucosa (arrow). Magnification: $\times 200$. (close-up view, $\times 1000$). (b) The absence of HLA-G expression in CD mucosal epithelium. Magnification: $\times 200$. (c) Expression of HLA-G in IECs in the epithelial layer in the intestinal mucosa in patients with UC (arrow). Magnification: $\times 200$. (d) An isotype-matched negative control IgG2a in patients with UC. Magnification: $\times 200$. (e) HLA-G in ulcerative colitis, strong positive signal in the ileal mucosal epithelium and crypt level. Peyer's patches showing negative signal (star). Magnification: $\times 200$.

These results support the essential role of IECs in the regulation of the mucosal immune response, an important role of these cells in the pathology of UC. Moreover, our results indicate a difference between CD and UC, and suggest that increased HLA-G expression might just be a consequence of the immune dysfunction characteristic of UC.

On the other hand, it is conceivable that HLA-G expression in UC might reflect a down-regulation of the immune response against inflammation, in addition to IL-10 production. Previous studies in trophoblast and monocytes have demonstrated that

HLA-G is inducible by IL-10 (18,19). Then, we tested for the presence of IL-10-producing cells in patients with UC and CD. Immunohistochemistry for IL-10 was performed on formalin-fixed tissues of patients with UC and CD, and the immunoreactivity was scored semiquantitatively. A strong IL-10 immunoreactivity was observed in the lamina propria cells in all UC HLA-G-positive cases (Fig. 2A). This cytokine was expressed mainly in inflammatory infiltrates enriched in macrophages, although T cells also seem to contribute to its production. IL-10 might bind to a specific receptor on IECs

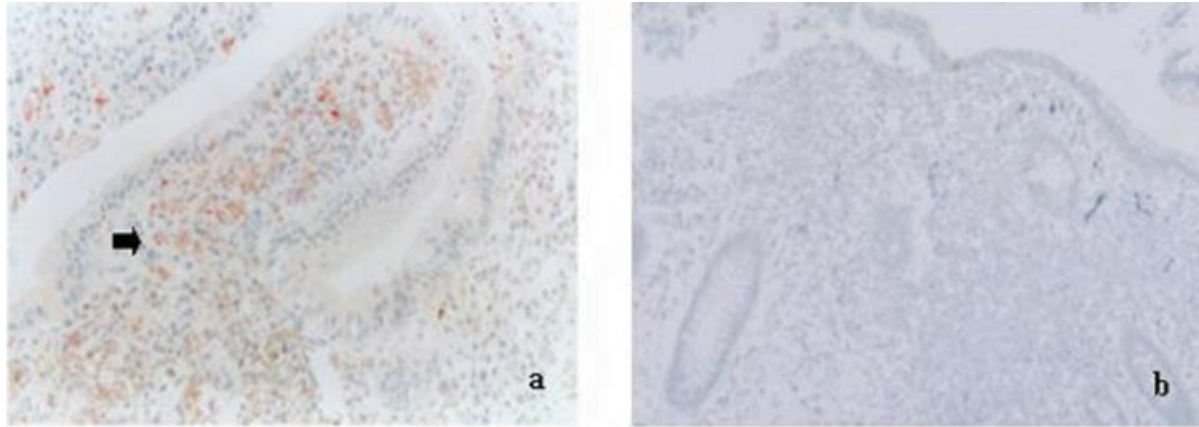


Fig. 2. (a) IL-10 strong immunoreactivity in the lamina propria cells of patients with UC ($n = 24$) (arrow). (b) Negative signal of IL-10 in lamina propria of patients with Crohn's disease ($n = 19$). Magnification $\times 200$.

and modulate the contribution of these cells to the inflammatory and immune response in the digestive tract.

Discussion

We demonstrate for the first time that in the inflamed mucosa of UC patients, the HLA-G molecule is strongly expressed on IECs, suggesting a protective role for these cells in such pathology. Indeed, it had been described that in addition to their important function in absorption and transport of nutrients, IECs play an important role in innate and adaptive immunity (20). In UC, the specific expression on the apical surface of IECs of HLA-G, a molecule involved in immune tolerance (21), would be essential in maintenance of tolerance to food antigens and gut microflora. This tolerance may be associated with this selective HLA-G expression in IECs. Also, HLA-G has a significant importance in the regulation of the response of lymphocyte to damaged IECs.

However, such expression is likely to be insufficient to protect the intestine from the inflammation induced by foreign antigens that are unsuccessfully eliminated from the mucosa, and from an acute immune response. In this sense, after aggression is stopped, HLA-G may participate in the suppression of the activity of pro-inflammatory cytokines, and in the return of the immune response to a basal state.

Since HLA-G is more widely expressed than originally believed, including on epithelial surfaces, and because this molecule suppresses NK lysis (22), mechanisms of NK inhibition may be operating in UC. Thus, HLA-G expression might protect IECs from NK-mediated lysis. Moreover, a previous report demonstrated that HLA-G regulates the Th1/Th2 cytokine balance in a way that may shift towards relative Th2 dominance (23). This is compatible with a possible role for Th2-type responses in UC.

IL-10 is a regulatory cytokine that plays a crucial role in the balance of the mucosal immune system, preventing the acute inflammation that characterizes IBD (24,25). IL-10 is important for the intestinal immune response and tolerance to components of intestinal flora. In its absence, luminal antigens stimulate a Th1-dependent response that leads to an intestinal inflammation. Changes in the microenvironment may create a

relative IL-10 deficit in the inflamed intestinal mucosa of CD patients. Alterations in the production of many cytokines have been described in patients with active IBD. We found that IL-10 was expressed in all patients with UC, and in all of the HLA-G positive cases, suggesting that IL-10 up-modulated HLA-G expression in this inflammatory disease, and that this cytokine may regulate the role of IECs in the inflammatory and immune response. The presence of receptor for IL-10 on IECs (26) makes this an attractive hypothesis. The intestinal mucosa is in a constant state of controlled inflammation, although the mechanisms implicated in this homeostasis are poorly understood.

HLA-G is a non-classical MHC molecule whose expression interferes with the function of immunocompetent NK and T cells, leading to immunological tolerance. HLA-G may thus recalibrate the delicate balance between tolerance and responsiveness in the intestinal mucosa. In addition to IL-10 production, HLA-G expression might be one way to down-regulate the immune response in UC.

The differential expression of HLA-G in UC and CD may be linked to differences in the pathogenesis of these two diseases. Moreover, it may be relevant to discern between these two inflammatory diseases for diagnostic purposes. Although the etiologic agents responsible for IBD have not yet been elucidated, our results may help to understand the inflammatory process in IBD. An improved knowledge of the mechanisms implicated in the expression and secretion of HLA-G during IBD will allow future therapeutic approaches aimed at preventing tissue damage.

Acknowledgements

We are grateful to Karen Shashok for translating the original manuscript into English.

References

- 1 Fiocchi, C. 1998. Inflammatory bowel disease: etiology and pathogenesis. *Gastroenterology* 115:182.
- 2 Stallmach, A., Strober, W., MacDonald, T. T., Lochs, H. and Zeitl, M. 1998. Induction and modulation of gastrointestinal inflammation. *Immunol. Today* 19:438.

- 3 Brandtzaeg, P., Haraldsen, G., Helgeland, L., Nilsen, E. M. and Rugtveit, J. 1999. New insights into the immunopathology of human inflammatory bowel disease. *Drugs Today* 35 (suppl A):33.
- 4 Shanahan, F. 2001. Inflammatory bowel disease: immunodiagnostics, immunotherapeutics, and ecotherapeutics. *Gastroenterology* 120:662.
- 5 Elson, C. O. 2000. Commensal bacteria as targets in Crohn's disease. *Gastroenterology* 119:254.
- 6 Dohi, T., Fujihashi, K., Rennert, P. D., Iwatani, K., Kiyono, H., McGhee, J. R. *et al.* 1999. Hapten-induced colitis is associated with colonic patch hypertrophy and T helper cell 2-type responses. *J. Exp. Med.* 189:1169.
- 7 Schreiber, S., Heining, T., Thiele, H. G. and Raedler, A. 1995. Immunoregulatory role of interleukin 10 in patients with inflammatory bowel disease. *Gastroenterology* 108:1434.
- 8 Rouas-Freiss, N., Goncalves, R. M., Menier, C., Dausset, J. and Carosella, E. D. 1997. Direct evidence to support the role of HLA-G in protecting the fetus from maternal uterine natural killer cytotoxicity. *Proc. Natl Acad. Sci. USA* 94:11520.
- 9 McMaster, M., Zhou, Y., Shorter, S., Kapasi, K., Geraghty, D., Lim, K. H., Fisher, S. *et al.* 1998. HLA-G isoforms produced by placental cytotrophoblasts and found in amniotic fluid are due to unusual glycosylation. *J. Immunol.* 160:5922.
- 10 Hunt, J. S., Petroff, M. G., Morales, P., Sedlmayr, P., Geraghty, D. E. and Ober, C. 2000. HLA-G in reproduction: studies on the maternal-fetal interface. *Hum. Immunol.* 61:1113.
- 11 Carosella, E. D. 2000. HLA-G: fetomaternal tolerance. *C. R. Acad. Sci. III* 323:675.
- 12 Riteau, B., Rouas-Freiss, N., Menier, C., Paul, P., Dausset, J. and Carosella, E. D. 2001. HLA-G2, -G3, and -G4 isoforms expressed as nonmature cell surface glycoproteins inhibit NK and antigen-specific CTL cytotoxicity. *J. Immunol.* 166:5018.
- 13 Paul, P., Cabestre, F. A., Ibrahim, E. C., Lefebvre, S., Khalil-Daher, I., Vazeux, G., Quiles, R. M., Bermond, F., Dausset, J. and Carosella, E. D. 2000. Identification of HLA-G7 as a new splice variant of the HLA-G mRNA and expression of soluble HLA-G5, -G6, and -G7 transcripts in human transfected cells. *Hum. Immunol.* 61:1138.
- 14 Lila, N., Rouas-Freiss, N., Dausset, J., Carpentier, A. and Carosella, E. D. 2001. Soluble HLA-G protein secreted by allo-specific CD4⁺ T cells suppresses the allo-proliferative response: a CD4⁺ T cell regulatory mechanism. *Proc. Natl Acad. Sci. USA* 98:12150.
- 15 Cabestre, F. A., Lefebvre, S., Moreau, P., Rouas-Freiss, N., Dausset, J., Carosella, E. D. and Paul, P. 1999. HLA-G expression: immune privilege for tumour cells? *Semin. Cancer Biol.* 9:27.
- 16 Ibrahim, E. C., Guerra, N., Lacombe, M. J., Angevin, E., Chouaib, S., Carosella, E. D., Caignard, A. and Paul, P. 2001. Tumor-specific up-regulation of the nonclassical class I HLA-G antigen expression in renal carcinoma. *Cancer Res.* 61:6838.
- 17 Lila, N., Carpentier, A., Amrein, C., Khalil-Daher, I., Dausset, J. and Carosella, E. D. 2000. Implication of HLA-G molecule in heart-graft acceptance. *Lancet* 355:2138.
- 18 Moreau, P., Adrian-Cabestre, F., Menier, C., Guiard, V., Gourand, L., Dausset, J., Carosella, E. D. and Paul, P. 1999. IL-10 selectively induces HLA-G expression in human trophoblasts and monocytes. *Int. Immunol.* 11:803.
- 19 Urošević, M., Willers, J., Mueller, B., Kempf, W., Burg, G. and Dummer, R. 2002. HLA-G protein up-regulation in primary cutaneous lymphomas is associated with interleukin-10 expression in large cell T-cell lymphomas and indolent B-cell lymphomas. *Blood* 99:609.
- 20 Christ, A. D. and Blumberg, R. S. 1997. The intestinal epithelial cells: immunological aspects. *Springer Semin. Immunopathol.* 18:449.
- 21 Rouas-Freiss, N., Paul, P., Dausset, J. and Carosella, E. D. 2000. HLA-G promotes immune tolerance. *J. Biol. Regul. Homeost. Agents* 14:93.
- 22 Pazmany, L., Mandelboim, O., Valés-Gómez, M., Davis, D. M., Reyburn, H. T. and Strominger, J. L. 1996. Protection from natural killer cell-mediated lysis by HLA-G expression on target cells. *Science* 274:792.
- 23 Kanai, T., Fujii, T., Unno, N., Yamashita, T., Hyodo, H., Miki, A., Hamai, Y., Kozuma, S. and Taketani, Y. 2001. Human leukocyte antigen-G-expressing cells differently modulate the release of cytokines from mononuclear cells present in the decidua versus peripheral blood. *Am. J. Reprod. Immunol.* 45:94.
- 24 Fiorentino, D. F., Zlotnik, A., Vieira, P., Mosmann, T. R., Howard, M., Moore, K. W. and O'Garra, A. 1991. IL-10 acts on the antigen presenting cell to inhibit cytokine production by Th1 cells. *J. Immunol.* 146:3444.
- 25 Asseman, C., Mauze, S., Leach, M. W., Coffman, R. L. and Powrie, F. 1999. An essential role for interleukin 10 in the function of regulatory T cells that inhibit intestinal inflammation. *J. Exp. Med.* 190:995.
- 26 Denning, T. L., Campbell, N. A., Song, F., Garofalo, R. P., Klimpel, G. R., Reyes, V. E. and Ernst, P. B. 2000. Expression of IL-10 receptors on epithelial cells from the murine small and large intestine. *Int. Immunol.* 12:133.